Patient: **117600 - Anthony Alexander**
DOB: **06/05/1995**
SSN:

Date: **09/19/2024 09:00**
Provider: **Brown, Joshua NP**
Encounter: **NEW PATIENT**

CHIEF COMPLAINT

neck and back pain, headaches

HISTORY OF PRESENT ILLNESS

This is the initial evaluation of a 29-year-old male who was involved in a motor vehicle accident on August 31, 2024. At the time of impact, the patient was the restrained individual sitting in the relaxed position. Patient was rear ended. The point of impact was in the back driver side of the vehicle. he recalls his head moving forward and backward hitting the steering well. Patient did not lose consciousness. The patient was able to get out of the vehicle on his own. Airbag did not deploy. Vehicle was totaled. EMS was involved at the scene. Patient did get transported via private transportation to Piedmont Atlanta Hospital. Patient received ibuprofen. Pain level today is a 7/10. This pain is a throbbing and sharp pain that is worse with movement. Denies fever, chills, nausea, vomiting, bowel incontinence, bladder incontinence, chest pain, abdominal pain, difficulty breathing, change in level of conciousness, and bruising.

CURRENT MEDICATION
Denies

PAST MEDICAL/SURGICAL HISTORY
Denies

ALLERGIES
NKDA

FAMILY HISTORY
Denies

SOCIAL HISTORY
Denies ETOH, TOBACCO AND ILLICIT DRUG USE

REVIEW OF SYSTEMS

CONSTITUTIONAL: No fever. No chills. No dizziness. + weakness.
EYES: No pain, erythema, or discharge. No blurring of vision.

Patient: **117600 - Anthony Alexander**
DOB: **06/05/1995**
SSN:

Date: **09/19/2024 09:00**
Provider: **Brown, Joshua NP**
Encounter: **NEW PATIENT**

ENT: No sore throat, URI symptoms. No epistaxis. No tinnitus.
CARDIOVASCULAR: No chest pain. No palpitations. No lower extremity edema.
RESPIRATORY: No shortness of breath, cough, pain with respiration, pleuritic chest pain. No hemoptysis. No dyspnea. No paroxysmal nocturnal dyspnea.
GASTROINTESTINAL: Normal appetite. No nausea, vomiting, diarrhea. No pain. No bloating. No melena.
GENITOURINARY: No frequency, urgency, nocturia. No hematuria or dysuria.
INTEGUMENTARY: No swelling. No bruising. No contusions. No abrasions.
PSYCHIATRIC: No confusion. No anxiety.
ENDOCRINE: + fatigue. No weakness. No extreme urination or thirst. No cold or heat intolerance.
NEUROLOGIC: Admits to headache.
MUSCULOSKELETAL: + myalgias back and neck muscles

PHYSICAL FINDINGS

- Vitals taken 09/19/2024 09:45 am

BP-Sitting	131/92 mmHg
Pulse Rate-Sitting	87 bpm
Temp-Temporal	97.6 F

Mental Status: Alert and oriented x4, NAD
Gait: Normal, slow, steady, balanced
HEENT: Head normocephalic and atraumatic, PERRLA
Chest: No tenderness to palpation
Heart: RRR, no murmur, gallop, or heave
Respirations: Even and unlabored, non-shallow
Abdomen: No tenderness to palpation, bowel sounds present in all four quadrants
Integumentary: No Bruises or lacerations
Neurological: Cranial Nerves II-XII are grossly intact
Cervical: Paraspinal Tenderness, Midline Tenderness, Active Spasm,trapezius muscle tenderness, Limited Left and Right Rotation, Limited Flexion, Limited Extension
Thoracic: Paraspinal Tenderness, Midline Tenderness
Lumbar Spine: Paraspinal Tenderness, midline tenderness, active spasm, limited forward flexion, limied lateral flexion, positive FABERs test, Positive Lumbar distraction test, Positive SIJ tenderness
Extremities: WNL

ASSESSMENT

Acute Pain Due to Trauma G89.11
Myofascial Pain Syndrome M79.1

Patient: **117600 - Anthony Alexander**
DOB: **06/05/1995**
SSN:

Date: **09/19/2024 09:00**
Provider: **Brown, Joshua NP**
Encounter: **NEW PATIENT**

Cervical strain/sprain, S13.4
Lumbar strain/sprain, S33.5
Neck pain, M54.2
Low back pain, M54.5
Muscle spasm of neck, M62.838
Muscle spasm of back, M62.830

Secondary to the accident

PLAN

due to physical exam findings, we will obtain a MRI of the Cervical Spine and Lumbar Spine. Patient was advised to Continue provider instructed home exercise program. Patient was instructed to apply hot/cold packs. Patient was Advised to stretch and Massage. Due to limited ROM and subjective and objective findings, we will have chiropractic Therapy to co-manage patient. Patient given a Tens Unit, Back Brace, pain cream, and Ice/ Heat Pack and verbalized understanding of proper use.

Patient admits to debilitating headaches, Denies photosensitivity, and Denies dizziness. In the absence of post concussion syndrome, will hold Neuro referral. Advised to avoid bright lights and loud sounds. Advised to stay hydrated, eat protein, and eat foods rich in Omega- 3s. Advised to avoid screen time and to limit swift movements with head and neck

F/u in 2 weeks

In my medical opinion, the patient's treatment thus far has been appropriate for the injuries they occurred. In my opinion, the patient's injuries are a direct result of the motor vehicle accident that occurred and their complaints are consistent with the mechanism of injury.

DISCLAIMER: This document was created using voice recognition software. Any mistakes in the transcription are not intentional. An attempt was made to proofread for accuracy, but to expedite availability, some errors may persist. Please contact our Medical Records Department with any need for corrections or further clarification.

Joshua Brown NP
Electronically signed by: Joshua Brown Date: 09/19/2024 14:37

Patient: **117600 - Anthony Alexander**
DOB: **06/05/1995**
SSN:

Date: **09/19/2024 09:00**
Provider: **Brown, Joshua NP**
Encounter: **NEW PATIENT**

Electronically approved by: Joshua Brown Date: 09/19/24 14:37

ADVANCED IMAGING CENTERS

PATIENT:	ALEXANDER, ANTHONY
DOB:	6/5/1995
FILE #:	2466413
PHYSICIAN:	DEARBORN, MARY
EXAMS:	MRI CERVICAL WITHOUT CONTRAST
DATE:	10/14/2024 5:13:48 PM

MRI OF THE CERVICAL SPINE:

HISTORY: Neck pain following a motor vehicle collision dated 8/31/2024.

TECHNIQUE: Multisequence T1 and T2 weighted images were obtained.

FINDINGS: The posterior fossa structures are normal. The cervical cord structures are normal. There is loss of the normal lordotic curvature of the cervical spine. In the correct clinical setting, this may reflect injury. Clinical correlation is recommended. No prevertebral or paravertebral masses or fluid collections are identified.

There is fluid between the clivus and the odontoid process, and this tracks along the alar ligaments. This finding is associated with whiplash associated disorder.

Segmental analysis of the cervical spine is as follows:

At C2-3, there is no evidence for disc herniation, canal stenosis or neural foraminal stenosis.

At C3-4, there is no evidence for disc herniation, canal stenosis or neural foraminal stenosis.

At C4-5, there is no evidence for disc herniation, canal stenosis or neural foraminal stenosis.

At C5-6, there is no evidence for disc herniation, canal stenosis or neural foraminal stenosis.

At C6-7, there is no evidence for disc herniation, canal stenosis or neural foraminal stenosis.

At C7-T1, there is no evidence for disc herniation, canal stenosis or neural foraminal stenosis.

IMPRESSION:

1. There is fluid between the clivus and the odontoid process, and this tracks along the alar ligaments. This finding is associated with whiplash associated disorder. **See Figure 1, Image 7, Series 5.** This is a STIR image where fluid is bright. The circled arrow demonstrates edema at the craniocervical junction.

2. Given this patient's age, history, and findings, there are acute findings on this examination, and clinical correlation is recommended to determine whether they are related to the patient's symptoms and the event in the history. Specifically, the edema at the craniocervical junction.

FIGURE 1

The definitions in this report, including definitions of disc bulge, herniation, protrusion, and extrusion, are from the following peer reviewed journal: Lumbar Disc Nomenclature V2.0, Recommendations of the Combined Task Forces of The North American Spine Society, The American Society of Spine Radiology and The American Society of Neuroradiology, The Spine Journal 14 (2014) 2525-2545. References to causation and permanency follow guidelines established by The American Medical Association. Note that a normal MRI does not exclude certain pathologies, including pathologies involving the nerves and facet joints. A normal MRI should not supersede abnormalities detected with physical exam.

Thank you for your kind referral.

SEAN M. MAHAN, M.D.
ELITERAD RADIOLOGY GROUP
CERTIFIED, AMERICAN BOARD OF RADIOLOGY

SMM/TR

ADVANCED IMAGING CENTERS

PATIENT:	ALEXANDER, ANTHONY
DOB:	6/5/1995
FILE #:	2466416
PHYSICIAN:	DEARBORN, MARY
EXAMS:	MRI LUMBAR WITHOUT CONTRAST
DATE:	10/14/2024 5:27:52 PM

MRI OF THE LUMBAR SPINE:

HISTORY: Low back pain following a motor vehicle collision dated 08/31/2024.

TECHNIQUE: Multisequence T1 and T2 weighted images were obtained.

FINDINGS: The conus medullaris appears normal. The lordotic curvature of the lumbar spine is preserved. No evidence for abnormal solid or cystic lesions is identified. No prevertebral or paravertebral masses or fluid collections are seen and there is no evidence for abnormal marrow replacing lesion. Segmental analysis of the lumbar spine is as follows:

At L1-2, there is no evidence for disc herniation, canal stenosis or neural foraminal stenosis.

At L2-3, there is no evidence for disc herniation, canal stenosis or neural foraminal stenosis.

At L3-4, there is no evidence for disc herniation, canal stenosis or neural foraminal stenosis.

At L4-5, there is no evidence for disc herniation, canal stenosis or neural foraminal stenosis.

At L5-S1, there is a posterior subligamentous herniated disc. There are no osteophytes or degenerative changes associated with this herniating disc. The herniated disc extends beyond the bone. This results in anterior impression on the thecal sac. There is no left or right neural foraminal stenosis present.

IMPRESSION:

1. At L5-S1, there is a posterior subligamentous herniated disc. There are no osteophytes or degenerative changes associated with this herniating disc. The herniated disc extends beyond the bone. This results in anterior impression on the thecal sac. **See figure 1, image 8, series 3.** The arrow is pointing to the L5-S1 herniated disc. **See figure 2, image 24, series 6.** The arrow is pointing to the L5-S1 herniated disc. There is a focal convexity of less than 25% of the disc, and by definition this is a herniated disc.
2. Given this patient's age, history, and findings, there are acute findings on this examination, and clinical correlation is recommended to determine whether they are related to the patient's symptoms and the event in the history. Specifically, the L5-S1 herniated disc.

FIGURE 1

ALEXANDER^ANTHONY
6/5/1995 M
ID: 1200857
H
10/14/2024
Ser: 3
Img: 8
Sagittal
A
P
C-
C247.97 W695.9 S0.0 U0.0
F
JPEG 2000 Lossy 3:1
Tech:
MRC35123
EXPRESS MRI

FIGURE 2

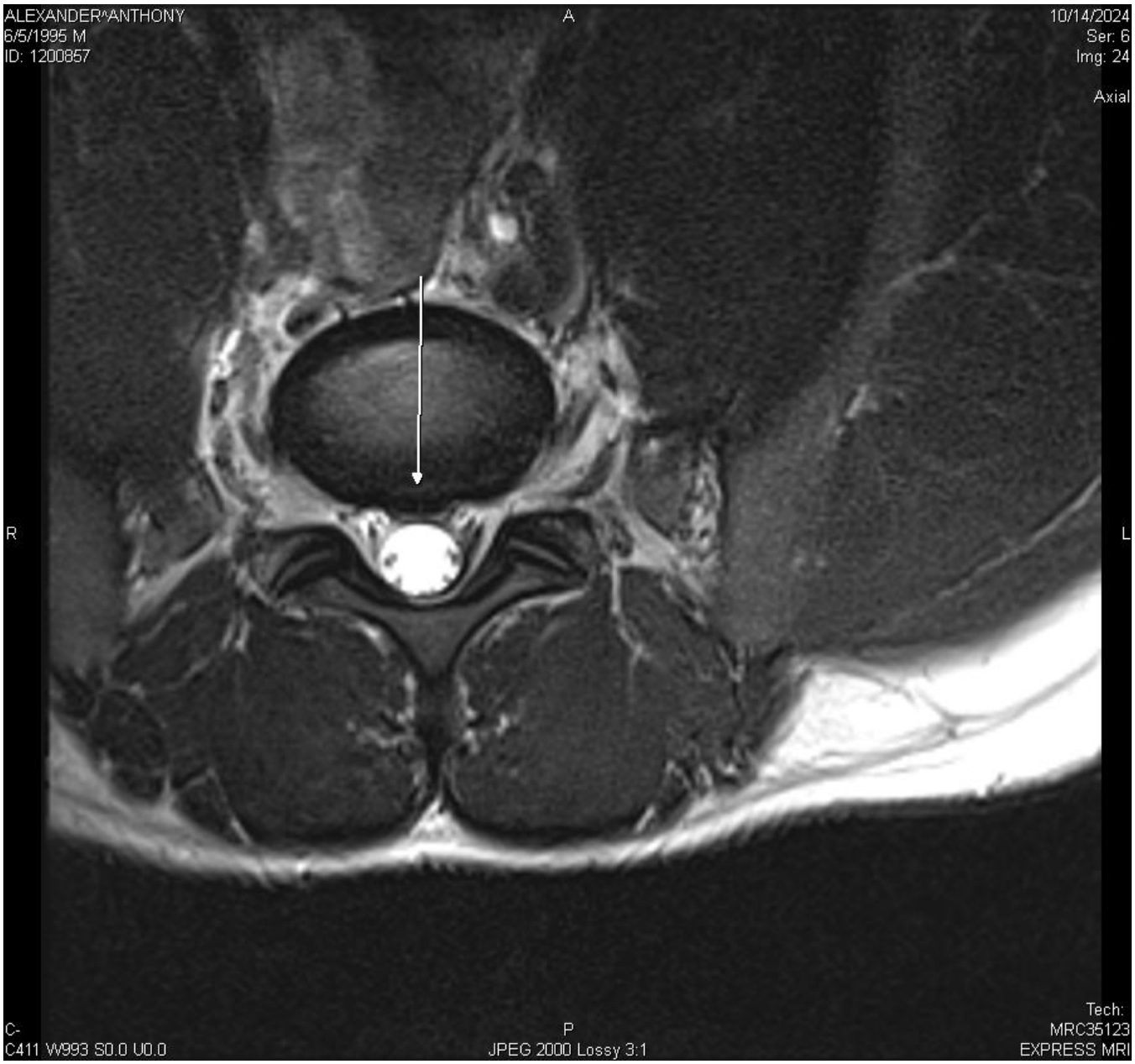

The definitions in this report, including definitions of disc bulge, herniation, protrusion, and extrusion, are from the following peer reviewed journal: Disc Nomenclature V2.0, Recommendations of the Combined Task Forces of the North American Spine Society, the American Society of Spine Radiology and the American Society of Neuroradiology, The Spine Journal 14 (2014) 2525-2545. References to causation and permanency follow guidelines established by the American Medical Association. Note that a normal MRI does not exclude certain pathologies, including pathologies involving the nerves and facet joints. A normal MRI should not supersede abnormalities detected with physical exam. Disc herniations are contained herniated discs unless specifically identified as uncontained.

Thank you for your kind referral.

SEAN M. MAHAN, M.D.
ELITERAD RADIOLOGY GROUP
CERTIFIED, AMERICAN BOARD OF RADIOLOGY

SMM/TB

Iceberg Health Morrow
1544 Southlake Pkwy
Unit 9F
Morrow, GA 30260-0287
(678) 505-0000

Initial Exam

Patient Name: Anthony Alexander, Jr
Date of Birth: 6/5/1995

Provider: Mary Dearborn, DC
Date of Service: 9/13/2024

SUBJECTIVE

HISTORY OF PRESENT ILLNESS

He has never experienced this condition before.

PRIMARY COMPLAINT

Head

- Throbbing, Sharp pain: 8/10
  Described as constant (up to 100% of day) of severe intensity (symptom is not alleviated by any amount of modification to ADL); increased by working, changing positions and ADL's; decreased by Prescribed Pain Medication.

SECOND COMPLAINT

Neck

- Sharp pain: 8/10
  Described as occasional (up to 25% of day) of severe intensity (symptom is not alleviated by any amount of modification to ADL); increased by sleeping, standing, sitting, lifting, walking, running, bending, working, driving, changing positions and ADL's; decreased by Prescribed Pain Medication.

THIRD COMPLAINT

Mid back

- Sharp pain: 8/10
  Described as frequent (up to 75% of day) of severe intensity (symptom is not alleviated by any amount of modification to ADL); increased by sleeping, standing, sitting, lifting, walking, running, bending, working, driving, changing positions and ADL's; decreased by rest.

FOURTH COMPLAINT

Low back

- Sharp pain: 8/10
  Described as frequent (up to 75% of day) of severe intensity (symptom is not alleviated by any amount of modification to ADL); increased by sleeping, standing, sitting, lifting, walking, running, bending, working, driving, changing positions and ADL's; decreased by rest.

PAST, FAMILY, SOCIAL HISTORY

Surgeries/Hospitalizations: none
Allergies: seasonal allergies
Medications: none
Prior conditions: None

Father: in good health
Mother: in good health
maternal grandfather had a stroke and psoriasis

REVIEW OF SYSTEMS

ALLERGIC-IMMUNOLOGIC: Allergies
CARDIOVASCULAR: Chest pain
EAR/NOSE/THROAT: Ringing in ears
EYES: Light bothers eyes
GASTROINTESTINAL: Constipation
MUSCULOSKELETAL: Stiffness, Neck pain and Back pain
NEUROLOGICAL: Headaches and Light Headed/Dizzy
PSYCHIATRIC: Anxiety, Mood swings, Difficult sleeping and Tension
GENERAL: Loss of sleep

The following are negative: CONSTITUTIONAL, ENDOCRINE, GENITOURINARY, HEMATOLOGY/LYMPH, RESPIRATORY, SKIN, OTHER and MEN'S HEALTH ISSUES.

Collision occurred on 8/31/2024 at approximately 11:18 PM.
I was driving on the express way and a speeding driver rear ended me.
Symptoms reported: I was diagnosed with a concussion. I have neck pain and back pain.

Mr. Alexander was the driver of the vehicle, a 2022 Nissan Sentra , at the time of the collision. There was rear damage to the vehicle. The collision happened while he was moving at 75 North in Atlanta, GA and occurred at night. The weather was clear. Street surface was dry. The impact on the vehicle was at the rear end. Upon impact, the brakes were locked, and the car did not move. Mr. Alexander was seated in the vehicle as a driver and was wearing a seat belt with the shoulder harness and with the headrest in up position. The vehicle is equipped with air bags and they did not deploy. Mr. Alexander didn't see the impact coming. Upon impact, his head was looking ahead and he was thrown forward. His head hit steering wheel . There was head trauma. Mr. Alexander remembers the collision happening.
He remained in Piedmont Healthcare for 5 Hours

* X-rays were taken of the neck, low-back, mid-back
* Medications given: Yes.
* Follow up instructions received: Appointment September 24th with my primary care physician.

The patient reports to this office due to injuries received in an MVC

OBJECTIVE

VITALS

Height: 69” in
Pulse rate: 58 BPM (relaxed)

Blood Pressure (seated): right -N/A left-121/79 mmHg

PALPATORY FINDINGS

Spinal asymmetry/fixation: C1; C5; C7; T3; T4; T6; T10; T11; T12; L2; Sacrum.

Tenderness

Left Side

- Cervical Spine (severe)
- Thoracic Spine (severe)
- Lower Back (severe)

Right Side

- Cervical Spine (severe)
- Thoracic Spine (severe)
- Lower Back (severe)

Spasm/Hypertonicity

Left Side

- Cervical Spine (moderate-severe)
- Thoracic Spine (moderate-severe)
- Lower Back (moderate-severe)

Right Side

- Cervical Spine (moderate-severe)
- Thoracic Spine (moderate-severe)
- Lower Back (moderate-severe)

GAIT

Ambulation: Normal.

Gait: Normal.

ORTHOPEDIC AND NEUROLOGICAL TESTS

Test	Left	Right	Comment
Cervical distraction [1]	Positive	Positive	
Foraminal compression test[2]	Positive	Positive	
Shoulder depression test[3]	Positive	Positive	
Spinal percussion test-cervical[4]	Positive	Positive	
Schepelmann's sign[5]	Positive	Positive	
Spinal percussion test-thoracic[6]	Positive	Positive	
Kemp's test[7]	Positive	Positive	
Straight leg raise[8]	Positive	Positive	
Bragard's test[9]	Positive	WNL	

[1]Relief of radicular pain suggests nerve root compression. Decreased local pain could indicate facet impingement. Increased local pain could indicate strain or sprain.

[2]Radicular pain could indicate pressure on the nerve root. Localized pain could indicate sprain or strain or foraminal encroachment.

[3]Pain in the arm could indicate adhesions of the nerve roots. Local pain could indicate sprain or strain or adhesions of the shoulder joint capsule.

[4]Localized pain suggests possible vertebral fracture. Radicular pain indicates possible disc lesion.

[5]Pain on the concave side may indicate intercostal neuritis. Pain on the convex side may be due to intercostal myofascitis.

[6]Localized pain suggests possible vertebral fracture. Radicular pain indicates possible disc lesion.

[7]Perhipheral pain in to the lower extremities indicates nerve root compression. Local pain may indicate sprain or strain.

[8]Perhipheral pain is suggestive of nerve root irritation, such as that due to a herniated disc.

[9]Increased peripheral pain may indicate neuritis, spinal nerve irritation, or a space occupying lesion.

REFLEXES

Biceps, Tricep, Brachioradialis, Patellar and Achilles are within normal limits bilaterally.

RANGE OF MOTION

Cervical ROM - estimated

Test	Measurement	Limited By	Comment
Flexion	35° (70% of normal)	Pain, Spasm, Guarding	
Extension	40° (66% of normal)	Pain, Spasm, Guarding	
Left lateral flexion	20° (44% of normal)	Pain, Spasm, Guarding	
Right lateral flexion	20° (44% of normal)	Pain, Spasm, Guarding	
Left rotation	45° (56% of normal)	Pain, Spasm, Guarding	
Right rotation	60° (75% of normal)	Pain, Spasm, Guarding	

Lumbar ROM - estimated

Test	Measurement	Limited By	Comment
Flexion	40° (66% of normal)	Pain, Spasm, Guarding	
Extension	15° (60% of normal)	Pain, Spasm, Guarding	
Left lateral flexion	15° (60% of normal)	Pain, Spasm, Guarding	
Right ateral flexion	15° (60% of normal)	Pain, Spasm, Guarding	
Left rotation	20° (66% of normal)	Pain, Spasm, Guarding	
Right rotation	20° (66% of normal)		

DERMATOMES

Posterior

Left-Cervical, Right-Cervical, Left-Lumbar and Right-Lumbar are within normal limits.

PHYSICAL EXAMINATION

General [well nourished, no acute distress]: WNL.
Skin [no skin sensitivity reported, free of lesions, rashes, eczema, upper/lower extremities]: WNL.
Head [eyes – symmetric appearance, conjunctiva white, no discharge, erythema, lid lag or swelling]: WNL.
Ears [no discharge or deformities noted to external ears]: WNL.
Nose [no sinus tenderness, epistaxis, or discharge]: WNL.
Oropharynx [lips free of lesions, cyanosis, no halitosis]: WNL.

Neck [supple, thyroroid non-palpable, no enlarged cervical lymph nodes palpable]: WNL.
Extremities – [upper/lower extremities free of edema, cyanosis, varicosities, cellulitis, pedal pulses 2+]: WNL.
Gross musculoskeletal deformities: WNL.

There are no contraindications to chiropractic care.

ASSESSMENT

Stage of Care: Acute

DIAGNOSES

1. Post-traumatic headache, unspecified, not intractable (G44.309)
2. Sprain of ligaments of cervical spine, initial encounter (S13.4XXA)
3. Sprain of ligaments of thoracic spine, initial encounter (S23.3XXA)
4. Sprain of ligaments of lumbar spine, initial encounter (S33.5XXA)
5. Strain of muscle, fascia and tendon at neck level, init (S16.1XXA)
6. Strain of muscle and tendon of back wall of thorax, init (S29.012A)
7. Strain of muscle, fascia and tendon of lower back, init (S39.012A)
8. Segmental and somatic dysfunction of cervical region (M99.01)
9. Segmental and somatic dysfunction of thoracic region (M99.02)
10. Segmental and somatic dysfunction of lumbar region (M99.03)
11. Cervicalgia (M54.2)
12. Pain in thoracic spine (M54.6)
13. Low back pain, unspecified (M54.50)
14. Muscle spasm of back (M62.830)
15. Sleep deprivation (Z72.820)
16. Person injured in unsp motor-vehicle accident, traffic, init (V89.2XXA)

PROGNOSIS

Guarded - The patient's condition is not expected to improve in the near future.

LONG-TERM GOALS

- Decrease pain to pre-injury status.
- Restore tolerance to normal activities of daily living.
- Promote soft tissue healing.
- Relieve pain and prevent recurrence.
- Increase pain-free ROM.
- Be able to perform normal ADL's.

COMPLICATING FACTORS

Contributing Conditions

- Auto Accident

Aggravating Conditions

- No contraindications to chiropractic manipulation
- ADL's

There is no past medical history that would contribute to the current exam findings. The current complaints are a result of this MVC.

PLAN

CARE PLAN DETAILS

Based on the findings, there will be 2 stages of care; Acute and Rehabilitative.

Based on the patient's condition, re-evaluations are planned, for each stage of care, to assess the benefits of care and ensure functional improvement.

During the **Acute stage**, the following services are expected to be provided:

- 98941 - CMT 3-4 Regions consisting of diversified technique and Instrument adjusting will be performed to the Neck and Back, to reduce pain reported at initial encounter by 50%. This will be provided 3 times per week for 3 weeks.
- 97014 - Electrical Stimulation consisting of interferential will be provided to reduce pain reported at initial encounter by 50%. This will be provided 3 times per week for 3 weeks.
- 97012 - Mechanical Traction consisting of intersegmental traction will be provided to reduce pain reported at initial encounter by 50%. This will be provided 3 times per week for 3 weeks.
- 97010 - Ice/Heat consisting of hot pack will be provided to reduce pain reported at initial encounter by 50%. This will be provided 3 times per week for 3 weeks.
- 99213 Re-evaluations will be performed once every 9 visits.

During the **Rehabilitative stage**, the following services are expected to be provided:

- 98941 - CMT 3-4 Regions consisting of diversified technique and Instrument adjusting will be performed to the Neck and Back, to reduce pain reported at initial encounter by 100%. This will be provided 3 times per week for 3 weeks.
- 97014 - Electrical Stimulation consisting of interferential will be provided to reduce pain reported at initial encounter by 100%. This will be provided 3 times per week for 3 weeks.
- 97012 - Mechanical Traction consisting of intersegmental traction will be performed to the Back and Neck, to reduce pain reported at initial encounter by 100%. This will be provided 3 times per week for 3 weeks.
- 97010 - Ice/Heat consisting of hot pack will be provided to reduce pain reported at initial encounter by 100%. This will be provided 3 times per week for 3 weeks.
- 99213 Re-evaluations will be performed once every 9 visits.

The patient will be re-evaluated at the end of care, with Est. pt. level 3, evaluation and management (99213), at which time the next phase of care will be discussed.

Care Plan and treatment are subject to change dependent on patient's compliance and response to care.

TODAY'S TREATMENT

Based on subjective and objective data, today's treatment consists of:

- CMT 3-4 Regions (98941) consisting of Instrument adjusting, diversified technique was provided specifically to C1; C5; C7; T3; T4; T6; T10; T11; T12; L2; Sacrum, to reduce pain

reported at initial encounter by 50%.

- Electrical Stimulation (97014) consisting of interferential was provided specifically to , to reduce pain reported at initial encounter by 50%.
- Mechanical Traction (97012) consisting of intersegmental traction was provided specifically to , to reduce pain reported at initial encounter by 50%.
- Ice/Heat (97010) consisting of hot pack was provided specifically to , to reduce pain reported at initial encounter by 50%.
- New Patient evaluation and management service, 99203, was provided today.

The patient had prior treatment. Will request records from the other health care providers. The patient presents today for a New Patient Exam. The course of care and treatment plan was discussed with the patient. The patient had an opportunity to ask questions and a treatment plan was given to the patient which will be 3 times per week for 3 weeks.

Patient received care without incident.

Mary Dearborn

(Electronic Signature)
Provider Name: Mary Dearborn, DC
Date: 09/13/2024 12:32 PM

Iceberg Health Morrow
1544 Southlake Pkwy
Unit 9F
Morrow, GA 30260-0287
(678) 505-0000

*Changes since previous Note have been **formatted differently.***

Daily Note

Patient Name: Anthony Alexander, Jr
Date of Birth: 6/5/1995

Provider: Mary Dearborn, DC
Date of Service: 9/17/2024

SUBJECTIVE

PRIMARY COMPLAINT
Head

- Throbbing, Sharp pain: **From 8 to 7/10 (10% decrease)**
  Described as **frequent to constant (up to between 75% and 100% of day)** of **moderate to severe intensity (symptom is not alleviated by any amount of modification to ADL)**; increased by working, changing positions and ADL's; decreased by Prescribed Pain Medication.

SECOND COMPLAINT
Neck

- Sharp pain: 8/10
  Described as occasional (up to 25% of day) of severe intensity (symptom is not alleviated by any amount of modification to ADL); increased by sleeping, standing, sitting, lifting, walking, running, bending, working, driving, changing positions and ADL's; decreased by Prescribed Pain Medication.

THIRD COMPLAINT
Mid back

- Sharp pain: 8/10
  Described as frequent (up to 75% of day) of severe intensity (symptom is not alleviated by any amount of modification to ADL); increased by sleeping, standing, sitting, lifting, walking, running, bending, working, driving, changing positions and ADL's; decreased by rest.

FOURTH COMPLAINT
Low back

- Sharp pain: 8/10
  Described as frequent (up to 75% of day) of severe intensity (symptom is not alleviated by any amount of modification to ADL); increased by sleeping, standing, sitting, lifting, walking, running, bending, working, driving, changing positions and ADL's; decreased by rest.

Says he **feels about** the **same today**.

OBJECTIVE

PALPATORY FINDINGS

Spinal asymmetry/fixation: C1; C5; C7; T3; T4; T6; T10; T11; T12; L2; Sacrum.

Tenderness

Left Side

- Cervical Spine (Severe)
- Thoracic Spine (Severe)
- Lower Back (Severe)

Right Side

- Cervical Spine (Severe)
- Thoracic Spine (Severe)
- Lower Back (Severe)

Spasm/Hypertonicity

Left Side

- Cervical Spine (Moderate-Severe)
- Thoracic Spine (Moderate-Severe)
- Lower Back (Moderate-Severe)

Right Side

- Cervical Spine (Moderate-Severe)
- Thoracic Spine (Moderate-Severe)
- Lower Back (Moderate-Severe)

ASSESSMENT

Stage of Care: Acute

DIAGNOSES

1. Post-traumatic headache, unspecified, not intractable (G44.309)
2. Sprain of ligaments of cervical spine, initial encounter (S13.4XXA)
3. Sprain of ligaments of thoracic spine, initial encounter (S23.3XXA)
4. Sprain of ligaments of lumbar spine, initial encounter (S33.5XXA)
5. Strain of muscle, fascia and tendon at neck level, init (S16.1XXA)
6. Strain of muscle and tendon of back wall of thorax, init (S29.012A)
7. Strain of muscle, fascia and tendon of lower back, init (S39.012A)
8. Segmental and somatic dysfunction of cervical region (M99.01)
9. Segmental and somatic dysfunction of thoracic region (M99.02)
10. Segmental and somatic dysfunction of lumbar region (M99.03)
11. Cervicalgia (M54.2)
12. Pain in thoracic spine (M54.6)
13. Low back pain, unspecified (M54.50)
14. Muscle spasm of back (M62.830)
15. Sleep deprivation (Z72.820)
16. Person injured in unsp motor-vehicle accident, traffic, init (V89.2XXA)

PROGNOSIS

Guarded - The patient's condition is not expected to improve in the near future.

COMPLICATING FACTORS

Contributing Conditions

- Auto Accident

Aggravating Conditions

- No contraindications to chiropractic manipulation
- ADL's

PLAN

CARE PLAN DETAILS

Based on the findings, there will be 2 stages of care; Acute and Rehabilitative.

Based on the patient's condition, re-evaluations are planned, for each stage of care, to assess the benefits of care and ensure functional improvement.

During the **Acute stage**, the following services are expected to be provided:

- 98941 - CMT 3-4 Regions consisting of diversified technique and Instrument adjusting will be performed to the Neck and Back, to reduce pain reported at initial encounter by 50%. This will be provided 3 times per week for 3 weeks.
- 97014 - Electrical Stimulation consisting of interferential will be provided to reduce pain reported at initial encounter by 50%. This will be provided 3 times per week for 3 weeks.
- 97012 - Mechanical Traction consisting of intersegmental traction will be provided to reduce pain reported at initial encounter by 50%. This will be provided 3 times per week for 3 weeks.
- 97010 - Ice/Heat consisting of hot pack will be provided to reduce pain reported at initial encounter by 50%. This will be provided 3 times per week for 3 weeks.
- 99213 Re-evaluations will be performed once every 9 visits.

During the **Rehabilitative stage**, the following services are expected to be provided:

- 98941 - CMT 3-4 Regions consisting of diversified technique and Instrument adjusting will be performed to the Neck and Back, to reduce pain reported at initial encounter by 100%. This will be provided 3 times per week for 3 weeks.
- 97014 - Electrical Stimulation consisting of interferential will be provided to reduce pain reported at initial encounter by 100%. This will be provided 3 times per week for 3 weeks.
- 97012 - Mechanical Traction consisting of intersegmental traction will be performed to the Back and Neck, to reduce pain reported at initial encounter by 100%. This will be provided 3 times per week for 3 weeks.
- 97010 - Ice/Heat consisting of hot pack will be provided to reduce pain reported at initial encounter by 100%. This will be provided 3 times per week for 3 weeks.
- 99213 Re-evaluations will be performed once every 9 visits.

The patient will be re-evaluated at the end of care, with Est. pt. level 3, evaluation and management (99213), at which time the next phase of care will be discussed.

Care Plan and treatment are subject to change dependent on patient's compliance and response to care.

TODAY'S TREATMENT

Based on subjective and objective data, today's treatment consists of:

- CMT 3-4 Regions (98941) consisting of Instrument adjusting, diversified technique was provided specifically to C1; C5; C7; T3; T4; T6; T10; T11; T12; L2; Sacrum, to reduce pain

reported at initial encounter by 50%.

- Electrical Stimulation (97014) consisting of interferential was provided specifically to , to reduce pain reported at initial encounter by 50%.
- Mechanical Traction (97012) consisting of intersegmental traction was provided specifically to , to reduce pain reported at initial encounter by 50%.
- Ice/Heat (97010) consisting of hot pack was provided specifically to , to reduce pain reported at initial encounter by 50%.

Patient received care without incident.



(Electronic Signature)
Provider Name: Mary Dearborn, DC
Date: 09/17/2024 12:01 PM

Iceberg Health Morrow
1544 Southlake Pkwy
Unit 9F
Morrow, GA 30260-0287
(678) 505-0000

*Changes since previous Note have been **formatted differently.***

Daily Note

Patient Name: Anthony Alexander, Jr
Date of Birth: 6/5/1995

Provider: Amanda Ruiz, DC
Date of Service: 9/19/2024

SUBJECTIVE

PRIMARY COMPLAINT
Head

- Throbbing, Sharp pain: 7/10
  Described as frequent to constant (up to between 75% and 100% of day) of moderate to severe intensity (symptom is not alleviated by any amount of modification to ADL); increased by working, changing positions and ADL's; decreased by Prescribed Pain Medication.

SECOND COMPLAINT
Neck

- Sharp pain: 8/10
  Described as occasional (up to 25% of day) of severe intensity (symptom is not alleviated by any amount of modification to ADL); increased by sleeping, standing, sitting, lifting, walking, running, bending, working, driving, changing positions and ADL's; decreased by Prescribed Pain Medication.

THIRD COMPLAINT
Mid back

- Sharp pain: 8/10
  Described as frequent (up to 75% of day) of severe intensity (symptom is not alleviated by any amount of modification to ADL); increased by sleeping, standing, sitting, lifting, walking, running, bending, working, driving, changing positions and ADL's; decreased by rest.

FOURTH COMPLAINT
Low back

- Sharp pain: 8/10
  Described as frequent (up to 75% of day) of severe intensity (symptom is not alleviated by any amount of modification to ADL); increased by sleeping, standing, sitting, lifting, walking, running, bending, working, driving, changing positions and ADL's; decreased by rest.

OBJECTIVE

PALPATORY FINDINGS

Spinal asymmetry/fixation: C1; C5; C7; T3; T4; T6; T10; T11; T12; L2; Sacrum**.**

Tenderness

Left Side

- Cervical Spine (Severe)
- Thoracic Spine (Severe)
- Lower Back (Severe)

Right Side

- Cervical Spine (Severe)
- Thoracic Spine (Severe)
- Lower Back (Severe)

Spasm/Hypertonicity

Left Side

- Cervical Spine (Moderate-Severe)
- Thoracic Spine (Moderate-Severe)
- Lower Back (Moderate-Severe)

Right Side

- Cervical Spine (Moderate-Severe)
- Thoracic Spine (Moderate-Severe)
- Lower Back (Moderate-Severe)

ASSESSMENT

Stage of Care: Acute

DIAGNOSES

1. Post-traumatic headache, unspecified, not intractable (G44.309)
2. Sprain of ligaments of cervical spine, initial encounter (S13.4XXA)
3. Sprain of ligaments of thoracic spine, initial encounter (S23.3XXA)
4. Sprain of ligaments of lumbar spine, initial encounter (S33.5XXA)
5. Strain of muscle, fascia and tendon at neck level, init (S16.1XXA)
6. Strain of muscle and tendon of back wall of thorax, init (S29.012A)
7. Strain of muscle, fascia and tendon of lower back, init (S39.012A)
8. Segmental and somatic dysfunction of cervical region (M99.01)
9. Segmental and somatic dysfunction of thoracic region (M99.02)
10. Segmental and somatic dysfunction of lumbar region (M99.03)
11. Cervicalgia (M54.2)
12. Pain in thoracic spine (M54.6)
13. Low back pain, unspecified (M54.50)
14. Muscle spasm of back (M62.830)
15. Sleep deprivation (Z72.820)
16. Person injured in unsp motor-vehicle accident, traffic, init (V89.2XXA)

PROGNOSIS

Guarded - The patient's condition is not expected to improve in the near future.

PLAN

Based on subjective and objective data, today's treatment consists of:

- CMT 3-4 Regions (98941) consisting of Instrument adjusting, diversified technique, **Thompson technique** was provided specifically to C7; **T1**; T6; **T7**; **T8**; **L5**; **Pelvis**, to reduce pain reported at initial encounter by 50%.
- Electrical Stimulation (97014) consisting of interferential was provided specifically to , to reduce pain reported at initial encounter by 50%.

- Mechanical Traction (97012) consisting of intersegmental traction was provided specifically to , to reduce pain reported at initial encounter by 50%.
- Ice/Heat (97010) consisting of hot pack was provided specifically to , to reduce pain reported at initial encounter by 50%.

Patient received care without incident.

(Electronic Signature)
Provider Name: Amanda Ruiz, DC
Date: 09/19/2024 12:04 PM

Iceberg Health Morrow
1544 Southlake Pkwy
Unit 9F
Morrow, GA 30260-0287
(678) 505-0000

*Changes since previous Note have been **formatted differently.***

Daily Note

Patient Name: Anthony Alexander, Jr
Date of Birth: 6/5/1995

Provider: Mary Dearborn, DC
Date of Service: 9/24/2024

SUBJECTIVE

PRIMARY COMPLAINT
Head

- Throbbing, Sharp pain: **From 7 to 5/10 (20% decrease)**
  Described as **intermittent to frequent (up to between 50% and 75% of day)** of **slight to moderate intensity**; increased by working, changing positions and ADL's; decreased by Prescribed Pain Medication.

SECOND COMPLAINT
Neck

- Sharp pain: **From 8 to 6/10 (20% decrease)**
  Described as occasional (up to 25% of day) of **moderate intensity (requires significant or complete modification to ADL)**; increased by sleeping, standing, sitting, lifting, walking, running, bending, working, driving, changing positions and ADL's; decreased by Prescribed Pain Medication.

THIRD COMPLAINT
Mid back

- Sharp pain: **From 8 to 6/10 (20% decrease)**
  Described as **intermittent to frequent (up to between 50% and 75% of day)** of **moderate intensity (requires significant or complete modification to ADL)**; increased by sleeping, standing, sitting, lifting, walking, running, bending, working, driving, changing positions and ADL's; decreased by rest.

FOURTH COMPLAINT
Low back

- Sharp pain: **From 8 to 7/10 (10% decrease)**
  Described as **intermittent to frequent (up to between 50% and 75% of day)** of **moderate intensity (requires significant or complete modification to ADL)**; increased by sleeping, standing, sitting, lifting, walking, running, bending, working, driving, changing positions and ADL's; decreased by rest.

Says he feels a little better today.

OBJECTIVE

PALPATORY FINDINGS

Spinal asymmetry/fixation: C1; C5; C7; T3; T4; T6; T10; T11; T12; L2; Sacrum**.**

Tenderness

Left Side

- Cervical Spine **(decreased 5-10% to moderate-severe)**
- Thoracic Spine **(decreased 5-10% to moderate-severe)**
- Lower Back **(decreased 5-10% to moderate-severe)**

Right Side

- Cervical Spine **(decreased 5-10% to moderate-severe)**
- Thoracic Spine **(decreased 5-10% to moderate-severe)**
- Lower Back **(decreased 5-10% to moderate-severe)**

Spasm/Hypertonicity

Left Side

- Cervical Spine **(decreased 5-10% to moderate)**
- Thoracic Spine **(decreased 5-10% to moderate)**
- Lower Back (Moderate-Severe)

Right Side

- Cervical Spine **(decreased 5-10% to moderate)**
- Thoracic Spine **(decreased 5-10% to moderate)**
- Lower Back (Moderate-Severe)

ASSESSMENT

Stage of Care: Acute

DIAGNOSES

1. Post-traumatic headache, unspecified, not intractable (G44.309)
2. Sprain of ligaments of cervical spine, initial encounter (S13.4XXA)
3. Sprain of ligaments of thoracic spine, initial encounter (S23.3XXA)
4. Sprain of ligaments of lumbar spine, initial encounter (S33.5XXA)
5. Strain of muscle, fascia and tendon at neck level, init (S16.1XXA)
6. Strain of muscle and tendon of back wall of thorax, init (S29.012A)
7. Strain of muscle, fascia and tendon of lower back, init (S39.012A)
8. Segmental and somatic dysfunction of cervical region (M99.01)
9. Segmental and somatic dysfunction of thoracic region (M99.02)
10. Segmental and somatic dysfunction of lumbar region (M99.03)
11. Cervicalgia (M54.2)
12. Pain in thoracic spine (M54.6)
13. Low back pain, unspecified (M54.50)
14. Muscle spasm of back (M62.830)
15. Sleep deprivation (Z72.820)
16. Person injured in unsp motor-vehicle accident, traffic, init (V89.2XXA)

PROGNOSIS

Prognosis has changed from **Guarded to Fair** - The patient can expect to have a reduction of their symptom and may require ongoing rehabilitation.

PLAN

Based on subjective and objective data, today's treatment consists of:

- CMT 3-4 Regions (98941) consisting of Instrument adjusting, diversified technique, Thompson technique was provided specifically to **C1**; **C5**; **C7**; **T3**; **T4**; T6; **T10**; **T11**; **T12**; **L2**; **Sacrum**, to reduce pain reported at initial encounter by 50%.
- Electrical Stimulation (97014) consisting of interferential was provided specifically to , to reduce pain reported at initial encounter by 50%.
- Mechanical Traction (97012) consisting of intersegmental traction was provided specifically to , to reduce pain reported at initial encounter by 50%.
- Ice/Heat (97010) consisting of hot pack was provided specifically to , to reduce pain reported at initial encounter by 50%.

Patient received care without incident.



(Electronic Signature)
Provider Name: Mary Dearborn, DC
Date: 09/24/2024 11:57 AM

Iceberg Health Morrow
1544 Southlake Pkwy
Unit 9F
Morrow, GA 30260-0287
(678) 505-0000

*Changes since previous Note have been **formatted differently.***

Daily Note

Patient Name: Anthony Alexander, Jr
Date of Birth: 6/5/1995

Provider: Mary Dearborn, DC
Date of Service: 10/11/2024

SUBJECTIVE

PRIMARY COMPLAINT
Head

- Throbbing, Sharp pain: **From 5 to 4/10 (10% decrease)**
  Described as **occasional to intermittent (up to between 25% and 50% of day)** of **slight intensity (requires some modification to ADL)**; increased by working, changing positions and ADL's; decreased by Prescribed Pain Medication.

SECOND COMPLAINT
Neck

- Sharp pain: **From 6 to 5/10 (10% decrease)**
  Described as occasional (up to 25% of day) of moderate intensity (requires significant or complete modification to ADL); increased by sleeping, standing, sitting, lifting, walking, running, bending, working, driving, changing positions and ADL's; decreased by Prescribed Pain Medication.

THIRD COMPLAINT
Mid back

- Sharp pain: **From 6 to 5/10 (10% decrease)**
  Described as intermittent to frequent (up to between 50% and 75% of day) of moderate intensity (requires significant or complete modification to ADL); increased by sleeping, standing, sitting, lifting, walking, running, bending, working, driving, changing positions and ADL's; decreased by rest.

FOURTH COMPLAINT
Low back

- Sharp pain: **From 7 to 6/10 (10% decrease)**
  Described as intermittent to frequent (up to between 50% and 75% of day) of moderate intensity (requires significant or complete modification to ADL); increased by sleeping, standing, sitting, lifting, walking, running, bending, working, driving, changing positions and ADL's; decreased by rest.

OBJECTIVE

PALPATORY FINDINGS

Spinal asymmetry/fixation: C1; C5; C7; T3; T4; T6; T10; T11; T12; L2; Sacrum**.**

Tenderness

Left Side

- Cervical Spine **(decreased 5-10% to moderate)**
- Thoracic Spine **(decreased 5-10% to moderate)**
- Lower Back **(decreased 5-10% to moderate)**

Right Side

- Cervical Spine **(decreased 5-10% to moderate)**
- Thoracic Spine **(decreased 5-10% to moderate)**
- Lower Back **(decreased 5-10% to moderate)**

Spasm/Hypertonicity

Left Side

- Lower Back **(decreased 5-10% to moderate)**
- Cervical Spine (Moderate)
- Thoracic Spine (Moderate)

Right Side

- Lower Back **(decreased 5-10% to moderate)**
- Cervical Spine (Moderate)
- Thoracic Spine (Moderate)

ASSESSMENT

Stage of Care: Acute

DIAGNOSES

1. Post-traumatic headache, unspecified, not intractable (G44.309)
2. Sprain of ligaments of cervical spine, initial encounter (S13.4XXA)
3. Sprain of ligaments of thoracic spine, initial encounter (S23.3XXA)
4. Sprain of ligaments of lumbar spine, initial encounter (S33.5XXA)
5. Strain of muscle, fascia and tendon at neck level, initial encounter (S16.1XXA)
6. Strain of muscle and tendon of back wall of thorax, initial encounter (S29.012A)
7. Strain of muscle, fascia and tendon of lower back, initial encounter (S39.012A)
8. Segmental and somatic dysfunction of cervical region (M99.01)
9. Segmental and somatic dysfunction of thoracic region (M99.02)
10. Segmental and somatic dysfunction of lumbar region (M99.03)
11. Cervicalgia (M54.2)
12. Pain in thoracic spine (M54.6)
13. Low back pain, unspecified (M54.50)
14. Muscle spasm of back (M62.830)
15. Sleep deprivation (Z72.820)
16. Person injured in unspecified motor-vehicle accident, traffic, initial encounter (V89.2XXA)

PROGNOSIS

Fair - The patient can expect to have a reduction of their symptom and may require ongoing rehabilitation.

PLAN

Based on subjective and objective data, today's treatment consists of:

- CMT 3-4 Regions (98941) consisting of Instrument adjusting, diversified technique,

Thompson technique was provided specifically to C1; C5; C7; T3; T4; T6; T10; T11; T12; L2; Sacrum, to reduce pain reported at initial encounter by 50%.

- Electrical Stimulation (97014) consisting of interferential was provided specifically to , to reduce pain reported at initial encounter by 50%.
- Mechanical Traction (97012) consisting of intersegmental traction was provided specifically to , to reduce pain reported at initial encounter by 50%.
- Ice/Heat (97010) consisting of hot pack was provided specifically to , to reduce pain reported at initial encounter by 50%.

Patient received care without incident.



(Electronic Signature)
Provider Name: Mary Dearborn, DC
Date: 10/11/2024 09:21 AM

Iceberg Health Morrow
1544 Southlake Pkwy
Unit 9F
Morrow, GA 30260-0287
(678) 505-0000

*Changes since previous Note have been **formatted differently.***

Daily Note

Patient Name: Anthony Alexander, Jr
Date of Birth: 6/5/1995

Provider: Mary Dearborn, DC
Date of Service: 10/15/2024

SUBJECTIVE

PRIMARY COMPLAINT
Head

- Throbbing, Sharp pain: **From 4 to 3/10 (10% decrease)**
  Described as **occasional (up to 25% of day)** of **minimal to slight intensity (symptom is not alleviated by any amount of modification to ADL)**; increased by working, changing positions and ADL's; decreased by Prescribed Pain Medication.

SECOND COMPLAINT
Neck

- Sharp pain: **From 5 to 4/10 (10% decrease)**
  Described as occasional (up to 25% of day) of **slight to moderate intensity**; increased by sleeping, standing, sitting, lifting, walking, running, bending, working, driving, changing positions and ADL's; decreased by Prescribed Pain Medication.

THIRD COMPLAINT
Mid back

- Sharp pain: 5/10
  Described as **intermittent (up to 50% of day)** of moderate intensity (requires significant or complete modification to ADL); increased by sleeping, standing, sitting, lifting, walking, running, bending, working, driving, changing positions and ADL's; decreased by rest.

FOURTH COMPLAINT
Low back

- Sharp pain: **From 6 to 5/10 (10% decrease)**
  Described as **intermittent (up to 50% of day)** of moderate intensity (requires significant or complete modification to ADL); increased by sleeping, standing, sitting, lifting, walking, running, bending, working, driving, changing positions and ADL's; decreased by rest.

Says he feels about the same but his pain is starting to come/go.

OBJECTIVE

PALPATORY FINDINGS

Spinal asymmetry/fixation: C1; C5; C7; T3; T4; T6; T10; T11; T12; L2; Sacrum.

Tenderness

Left Side

- Cervical Spine (Moderate)
- Thoracic Spine (Moderate)
- Lower Back (Moderate)

Right Side

- Cervical Spine (Moderate)
- Thoracic Spine (Moderate)
- Lower Back (Moderate)

Spasm/Hypertonicity

Left Side

- Cervical Spine (Moderate)
- Thoracic Spine (Moderate)
- Lower Back (Moderate)

Right Side

- Cervical Spine (Moderate)
- Thoracic Spine (Moderate)
- Lower Back (Moderate)

ASSESSMENT

Stage of Care: Acute

DIAGNOSES

1. Post-traumatic headache, unspecified, not intractable (G44.309)
2. Sprain of ligaments of cervical spine, initial encounter (S13.4XXA)
3. Sprain of ligaments of thoracic spine, initial encounter (S23.3XXA)
4. Sprain of ligaments of lumbar spine, initial encounter (S33.5XXA)
5. Strain of muscle, fascia and tendon at neck level, initial encounter (S16.1XXA)
6. Strain of muscle and tendon of back wall of thorax, initial encounter (S29.012A)
7. Strain of muscle, fascia and tendon of lower back, initial encounter (S39.012A)
8. Segmental and somatic dysfunction of cervical region (M99.01)
9. Segmental and somatic dysfunction of thoracic region (M99.02)
10. Segmental and somatic dysfunction of lumbar region (M99.03)
11. Cervicalgia (M54.2)
12. Pain in thoracic spine (M54.6)
13. Low back pain, unspecified (M54.50)
14. Muscle spasm of back (M62.830)
15. Sleep deprivation (Z72.820)
16. Person injured in unspecified motor-vehicle accident, traffic, initial encounter (V89.2XXA)

PROGNOSIS

Fair - The patient can expect to have a reduction of their symptom and may require ongoing rehabilitation.

PLAN

Based on subjective and objective data, today's treatment consists of:

- CMT 3-4 Regions (98941) consisting of Instrument adjusting, diversified technique, Thompson technique was provided specifically to C1; C5; C7; T3; T4; T6; T10; T11; T12; L2; Sacrum, to reduce pain reported at initial encounter by 50%.
- Electrical Stimulation (97014) consisting of interferential was provided specifically to , to reduce pain reported at initial encounter by 50%.

- Mechanical Traction (97012) consisting of intersegmental traction was provided specifically to , to reduce pain reported at initial encounter by 50%.
- Ice/Heat (97010) consisting of hot pack was provided specifically to , to reduce pain reported at initial encounter by 50%.

Patient received care without incident.



(Electronic Signature)
Provider Name: Mary Dearborn, DC
Date: 10/15/2024 12:26 PM

Iceberg Health Morrow
1544 Southlake Pkwy
Unit 9F
Morrow, GA 30260-0287
(678) 505-0000

*Changes since previous Note have been **formatted differently.***

Daily Note

Patient Name: Anthony Alexander, Jr
Date of Birth: 6/5/1995

Provider: Mary Dearborn, DC
Date of Service: 10/17/2024

SUBJECTIVE

PRIMARY COMPLAINT
Head

- Throbbing, Sharp pain: 3/10
  Described as occasional (up to 25% of day) of minimal to slight intensity (symptom is not alleviated by any amount of modification to ADL); increased by working, changing positions and ADL's; decreased by Prescribed Pain Medication.

SECOND COMPLAINT
Neck

- Sharp pain: 4/10
  Described as occasional (up to 25% of day) of slight to moderate intensity; increased by sleeping, standing, sitting, lifting, walking, running, bending, working, driving, changing positions and ADL's; decreased by Prescribed Pain Medication.

THIRD COMPLAINT
Mid back

- Sharp pain: **From 5 to 4/10 (10% decrease)**
  Described as intermittent (up to 50% of day) of **slight to moderate intensity**; increased by sleeping, standing, sitting, lifting, walking, running, bending, working, driving, changing positions and ADL's; decreased by rest.

FOURTH COMPLAINT
Low back

- Sharp pain: 5/10
  Described as intermittent (up to 50% of day) of moderate intensity (requires significant or complete modification to ADL); increased by sleeping, standing, sitting, lifting, walking, running, bending, working, driving, changing positions and ADL's; decreased by rest.

Says he **is slowly** feeling **better**.

OBJECTIVE

PALPATORY FINDINGS
Spinal asymmetry/fixation: C1; C5; C7; T3; T4; T6; T10; T11; T12; L2; Sacrum**.**

Tenderness

Left Side

- Cervical Spine **(decreased 5-10% to mild-moderate)**
- Thoracic Spine **(decreased 5-10% to mild-moderate)**
- Lower Back (Moderate)

Right Side

- Cervical Spine **(decreased 5-10% to mild-moderate)**
- Thoracic Spine **(decreased 5-10% to mild-moderate)**
- Lower Back (Moderate)

Spasm/Hypertonicity

Left Side

- Cervical Spine **(decreased 5-10% to mild-moderate)**
- Thoracic Spine **(decreased 5-10% to mild-moderate)**
- Lower Back (Moderate)

Right Side

- Cervical Spine **(decreased 5-10% to mild-moderate)**
- Thoracic Spine **(decreased 5-10% to mild-moderate)**
- Lower Back (Moderate)

ASSESSMENT

Stage of Care: Acute

DIAGNOSES

1. Post-traumatic headache, unspecified, not intractable (G44.309)
2. Sprain of ligaments of cervical spine, initial encounter (S13.4XXA)
3. Sprain of ligaments of thoracic spine, initial encounter (S23.3XXA)
4. Sprain of ligaments of lumbar spine, initial encounter (S33.5XXA)
5. Strain of muscle, fascia and tendon at neck level, initial encounter (S16.1XXA)
6. Strain of muscle and tendon of back wall of thorax, initial encounter (S29.012A)
7. Strain of muscle, fascia and tendon of lower back, initial encounter (S39.012A)
8. Segmental and somatic dysfunction of cervical region (M99.01)
9. Segmental and somatic dysfunction of thoracic region (M99.02)
10. Segmental and somatic dysfunction of lumbar region (M99.03)
11. Cervicalgia (M54.2)
12. Pain in thoracic spine (M54.6)
13. Low back pain, unspecified (M54.50)
14. Muscle spasm of back (M62.830)
15. Sleep deprivation (Z72.820)
16. Person injured in unspecified motor-vehicle accident, traffic, initial encounter (V89.2XXA)

PROGNOSIS

Fair - The patient can expect to have a reduction of their symptom and may require ongoing rehabilitation.

PLAN

Based on subjective and objective data, today's treatment consists of:

- CMT 3-4 Regions (98941) consisting of Instrument adjusting, diversified technique, Thompson technique was provided specifically to C1; C5; C7; T3; T4; T6; T10; T11; T12; L2; Sacrum, to reduce pain reported at initial encounter by 50%.
- Electrical Stimulation (97014) consisting of interferential was provided specifically to , to reduce pain reported at initial encounter by 50%.

- Mechanical Traction (97012) consisting of intersegmental traction was provided specifically to , to reduce pain reported at initial encounter by 50%.
- Ice/Heat (97010) consisting of hot pack was provided specifically to , to reduce pain reported at initial encounter by 50%.

Patient received care without incident.



(Electronic Signature)
Provider Name: Mary Dearborn, DC
Date: 10/17/2024 12:31 PM

Iceberg Health Morrow
1544 Southlake Pkwy
Unit 9F
Morrow, GA 30260-0287
(678) 505-0000

*Changes since previous Note have been **formatted differently.***

Daily Note

Patient Name: Anthony Alexander, Jr
Date of Birth: 6/5/1995

Provider: Mary Dearborn, DC
Date of Service: 10/18/2024

SUBJECTIVE

PRIMARY COMPLAINT
Head

- Throbbing, Sharp pain: **From 3 to 2/10 (10% decrease)**
  Described as occasional (up to 25% of day) of minimal to slight intensity (symptom is not alleviated by any amount of modification to ADL); increased by working, changing positions and ADL's; decreased by Prescribed Pain Medication.

SECOND COMPLAINT
Neck

- Sharp pain: 4/10
  Described as occasional (up to 25% of day) of slight to moderate intensity; increased by sleeping, standing, sitting, lifting, walking, running, bending, working, driving, changing positions and ADL's; decreased by Prescribed Pain Medication.

THIRD COMPLAINT
Mid back

- Sharp pain: 4/10
  Described as intermittent (up to 50% of day) of slight to moderate intensity; increased by sleeping, standing, sitting, lifting, walking, running, bending, working, driving, changing positions and ADL's; decreased by rest.

FOURTH COMPLAINT
Low back

- Sharp pain: 5/10
  Described as intermittent (up to 50% of day) of moderate intensity (requires significant or complete modification to ADL); increased by sleeping, standing, sitting, lifting, walking, running, bending, working, driving, changing positions and ADL's; decreased by rest.

He states he **still gets headaches but notes they seem to be improving**. **He otherwise feels about the same**.

OBJECTIVE

PALPATORY FINDINGS

Spinal asymmetry/fixation: C1; C5; C7; T3; T4; T6; T10; T11; T12; L2; Sacrum.

Tenderness

Left Side

- Cervical Spine (Mild-Moderate)
- Thoracic Spine (Mild-Moderate)
- Lower Back (Moderate)

Right Side

- Cervical Spine (Mild-Moderate)
- Thoracic Spine (Mild-Moderate)
- Lower Back (Moderate)

Spasm/Hypertonicity

Left Side

- Cervical Spine (Mild-Moderate)
- Thoracic Spine (Mild-Moderate)
- Lower Back (Moderate)

Right Side

- Cervical Spine (Mild-Moderate)
- Thoracic Spine (Mild-Moderate)
- Lower Back (Moderate)

ASSESSMENT

Stage of Care: Acute

DIAGNOSES

1. Post-traumatic headache, unspecified, not intractable (G44.309)
2. Sprain of ligaments of cervical spine, initial encounter (S13.4XXA)
3. Sprain of ligaments of thoracic spine, initial encounter (S23.3XXA)
4. Sprain of ligaments of lumbar spine, initial encounter (S33.5XXA)
5. Strain of muscle, fascia and tendon at neck level, initial encounter (S16.1XXA)
6. Strain of muscle and tendon of back wall of thorax, initial encounter (S29.012A)
7. Strain of muscle, fascia and tendon of lower back, initial encounter (S39.012A)
8. Segmental and somatic dysfunction of cervical region (M99.01)
9. Segmental and somatic dysfunction of thoracic region (M99.02)
10. Segmental and somatic dysfunction of lumbar region (M99.03)
11. Cervicalgia (M54.2)
12. Pain in thoracic spine (M54.6)
13. Low back pain, unspecified (M54.50)
14. Muscle spasm of back (M62.830)
15. Sleep deprivation (Z72.820)
16. Person injured in unspecified motor-vehicle accident, traffic, initial encounter (V89.2XXA)

PROGNOSIS

Fair - The patient can expect to have a reduction of their symptom and may require ongoing rehabilitation.

PLAN

Based on subjective and objective data, today's treatment consists of:

- CMT 3-4 Regions (98941) consisting of Instrument adjusting, diversified technique, Thompson technique was provided specifically to C1; C5; C7; T3; T4; T6; T10; T11; T12; L2; Sacrum, to reduce pain reported at initial encounter by 50%.
- Electrical Stimulation (97014) consisting of interferential was provided specifically to , to reduce pain reported at initial encounter by 50%.

- Mechanical Traction (97012) consisting of intersegmental traction was provided specifically to , to reduce pain reported at initial encounter by 50%.
- Ice/Heat (97010) consisting of hot pack was provided specifically to , to reduce pain reported at initial encounter by 50%.

Patient received care without incident.



(Electronic Signature)
Provider Name: Mary Dearborn, DC
Date: 10/18/2024 12:11 PM

Iceberg Health Morrow
1544 Southlake Pkwy
Unit 9F
Morrow, GA 30260-0287
(678) 505-0000

*Changes since previous Note have been **formatted differently.***

Exam

Patient Name: Anthony Alexander, Jr
Date of Birth: 6/5/1995

Provider: Mary Dearborn, DC
Date of Service: 10/22/2024

SUBJECTIVE

PRIMARY COMPLAINT
Head

- Throbbing, Sharp pain: 2/10
  Described as occasional (up to 25% of day) of minimal to slight intensity (symptom is not alleviated by any amount of modification to ADL); increased by working, changing positions and ADL's; decreased by Prescribed Pain Medication.

SECOND COMPLAINT
Neck

- Sharp pain: **From 4 to 3/10 (10% decrease)**
  Described as occasional (up to 25% of day) of **slight intensity (requires some modification to ADL)**; increased by sleeping, standing, sitting, lifting, walking, running, bending, working, driving, changing positions and ADL's; decreased by Prescribed Pain Medication.

THIRD COMPLAINT
Mid back

- Sharp pain: 4/10
  Described as intermittent (up to 50% of day) of slight to moderate intensity; increased by sleeping, standing, sitting, lifting, walking, running, bending, working, driving, changing positions and ADL's; decreased by rest.

FOURTH COMPLAINT
Low back

- Sharp pain: **From 5 to 4/10 (10% decrease)**
  Described as intermittent (up to 50% of day) of moderate intensity (requires significant or complete modification to ADL); increased by sleeping, standing, sitting, lifting, walking, running, bending, working, driving, changing positions and ADL's; decreased by rest.

Says he **is noticing improvement but is** still **experiencing some discomfort**.

OBJECTIVE

VITALS

Height: 69” in
Pulse rate: 79 BPM (relaxed)
Blood Pressure (seated): right -N/A left-120/74 mmHg

PALPATORY FINDINGS

Spinal asymmetry/fixation: C1; C5; C7; T3; T4; T6; T10; T11; T12; L2; Sacrum**.**

Tenderness

Left Side

- Cervical Spine **(decreased 5-10% to mild)**
- Thoracic Spine (Mild-Moderate)
- Lower Back (Moderate)

Right Side

- Cervical Spine **(decreased 5-10% to mild)**
- Thoracic Spine (Mild-Moderate)
- Lower Back (Moderate)

Spasm/Hypertonicity

Left Side

- Cervical Spine **(decreased 5-10% to mild)**
- Thoracic Spine **(decreased 5-10% to mild)**
- Lower Back **(decreased 5-10% to mild-moderate)**

Right Side

- Cervical Spine **(decreased 5-10% to mild)**
- Thoracic Spine **(decreased 5-10% to mild)**
- Lower Back **(decreased 5-10% to mild-moderate)**

GAIT

Ambulation: Normal.
Gait: Normal.

ORTHOPEDIC AND NEUROLOGICAL TESTS

Test	Left	Right	Comment
Foraminal compression test[1]	Positive	Positive	
Shoulder depression test[2]	Positive	**WNL**	
Spinal percussion test-cervical[3]	Positive	Positive	
Schepelmann's sign[4]	Positive	**WNL**	
Spinal percussion test-thoracic[5]	Positive	Positive	
Kemp's test[6]	Positive	**WNL**	
Straight leg raise[7]	Positive	**WNL**	
Bragard's test[8]	Positive	WNL	

[1]Radicular pain could indicate pressure on the nerve root. Localized pain could indicate sprain or strain or foraminal encroachment.

[2]Pain in the arm could indicate adhesions of the nerve roots. Local pain could indicate sprain or strain or adhesions of the shoulder joint capsule.

[3]Localized pain suggests possible vertebral fracture. Radicular pain indicates possible disc lesion.

[4]Pain on the concave side may indicate intercostal neuritis. Pain on the convex side may be due to intercostal myofascitis.

[5]Localized pain suggests possible vertebral fracture. Radicular pain indicates possible disc lesion.

[6]Perhipheral pain in to the lower extremities indicates nerve root compression. Local pain may indicate sprain or strain.

[7]Perhipheral pain is suggestive of nerve root irritation, such as that due to a herniated disc.

[8]Increased peripheral pain may indicate neuritis, spinal nerve irritation, or a space occupying lesion.

Cervical distraction within normal limits.

REFLEXES

Biceps, Tricep, Brachioradialis, Patellar and Achilles are within normal limits bilaterally.

RANGE OF MOTION

Cervical ROM - estimated

Test	Measurement	Limited By	Comment
Flexion	**45° (90% of normal, increased by 28%)**	Pain, Spasm	
Extension	**50° (83% of normal, increased by 25%)**	Pain, Spasm	
Left lateral flexion	**35° (77% of normal, increased by 75%)**	Pain, Spasm	
Right lateral flexion	**35° (77% of normal, increased by 75%)**	Pain, Spasm	
Left rotation	**65° (81% of normal, increased by 44%)**	Pain, Spasm	
Right rotation	**70° (87% of normal, increased by 16%)**	Pain, Spasm	

Lumbar ROM - estimated

Test	Measurement	Limited By	Comment
Flexion	**50° (83% of normal, increased by 25%)**	Pain, Spasm	
Extension	**20° (80% of normal, increased by 33%)**	Pain, Spasm	
Left lateral flexion	**20° (80% of normal, increased by 33%)**	Pain, Spasm	
Right ateral flexion	**20° (80% of normal, increased by 33%)**	Pain, Spasm	
Left rotation	**25° (83% of normal, increased by 25%)**	Pain, Spasm	
Right rotation	**25° (83% of normal, increased by 25%)**	**Pain**, **Spasm**	

DERMATOMES

Posterior

Left-Cervical, Right-Cervical, Left-Lumbar and Right-Lumbar are within normal limits.

PHYSICAL EXAMINATION

General [well nourished, no acute distress]: WNL.
Skin [no skin sensitivity reported, free of lesions, rashes, eczema, upper/lower extremities]: WNL.
Head [eyes – symmetric appearance, conjunctiva white, no discharge, erythema, lid lag or swelling]: WNL.
Ears [no discharge or deformities noted to external ears]: WNL.
Nose [no sinus tenderness, epistaxis, or discharge]: WNL.
Oropharynx [lips free of lesions, cyanosis, no halitosis]: WNL.
Neck [supple, thyroroid non-palpable, no enlarged cervical lymph nodes palpable]: WNL.
Extremities – [upper/lower extremities free of edema, cyanosis, varicosities, cellulitis, pedal pulses 2+]: WNL.
Gross musculoskeletal deformities: WNL.

ASSESSMENT

Stage of Care: Acute

DIAGNOSES

1. Post-traumatic headache, unspecified, not intractable (G44.309)
2. Sprain of ligaments of cervical spine, initial encounter (S13.4XXA)
3. Sprain of ligaments of thoracic spine, initial encounter (S23.3XXA)
4. Sprain of ligaments of lumbar spine, initial encounter (S33.5XXA)
5. Strain of muscle, fascia and tendon at neck level, initial encounter (S16.1XXA)
6. Strain of muscle and tendon of back wall of thorax, initial encounter (S29.012A)
7. Strain of muscle, fascia and tendon of lower back, initial encounter (S39.012A)
8. Segmental and somatic dysfunction of cervical region (M99.01)
9. Segmental and somatic dysfunction of thoracic region (M99.02)
10. Segmental and somatic dysfunction of lumbar region (M99.03)
11. Cervicalgia (M54.2)
12. Pain in thoracic spine (M54.6)
13. Low back pain, unspecified (M54.50)
14. Muscle spasm of back (M62.830)
15. Sleep deprivation (Z72.820)
16. Person injured in unspecified motor-vehicle accident, traffic, initial encounter (V89.2XXA)

PROGNOSIS

Fair - The patient can expect to have a reduction of their symptom and may require ongoing rehabilitation.

Patient is **showing slight improvement** since the prior visit, He is **progressing as anticipated**.

PLAN

Based on subjective and objective data, today's treatment consists of:

- CMT 3-4 Regions (98941) consisting of Instrument adjusting, diversified technique, Thompson technique was provided specifically to C1; C5; C7; T3; T4; T6; T10; T11; T12; L2; Sacrum, to reduce pain reported at initial encounter by 50%.
- Electrical Stimulation (97014) consisting of interferential was provided specifically to , to reduce pain reported at initial encounter by 50%.
- Mechanical Traction (97012) consisting of intersegmental traction was provided

specifically to , to reduce pain reported at initial encounter by 50%.

- Ice/Heat (97010) consisting of hot pack was provided specifically to , to reduce pain reported at initial encounter by 50%.
- **Established Patient evaluation and management service, 99213, was provided today.**

MRI Results were reviewed today with the patient. The patient had the opportunity to ask questions and understand the findings. Reexam today. the new care plan will be 3 times per week for 3 weeks.

Patient received care without incident.



(Electronic Signature)
Provider Name: Mary Dearborn, DC
Date: 10/22/2024 12:19 PM

Iceberg Health Morrow
1544 Southlake Pkwy
Unit 9F
Morrow, GA 30260-0287
(678) 505-0000

*Changes since previous Note have been **formatted differently.***

Daily Note

Patient Name: Anthony Alexander, Jr
Date of Birth: 6/5/1995

Provider: Mary Dearborn, DC
Date of Service: 10/29/2024

SUBJECTIVE

PRIMARY COMPLAINT
Head

- Throbbing, Sharp pain: 2/10
  Described as occasional (up to 25% of day) of minimal to slight intensity (symptom is not alleviated by any amount of modification to ADL); increased by working, changing positions and ADL's; decreased by Prescribed Pain Medication.

SECOND COMPLAINT
Neck

- Sharp pain: 3/10
  Described as occasional (up to 25% of day) of slight intensity (requires some modification to ADL); increased by sleeping, standing, sitting, lifting, walking, running, bending, working, driving, changing positions and ADL's; decreased by Prescribed Pain Medication.

THIRD COMPLAINT
Mid back

- Sharp pain: **From 4 to 3/10 (10% decrease)**
  Described as intermittent (up to 50% of day) of slight to moderate intensity; increased by sleeping, standing, sitting, lifting, walking, running, bending, working, driving, changing positions and ADL's; decreased by rest.

FOURTH COMPLAINT
Low back

- Sharp pain: 4/10
  Described as intermittent (up to 50% of day) of moderate intensity (requires significant or complete modification to ADL); increased by sleeping, standing, sitting, lifting, walking, running, bending, working, driving, changing positions and ADL's; decreased by rest.

Says he **feels he** is **continuing to** improve

OBJECTIVE

PALPATORY FINDINGS

Spinal asymmetry/fixation: C1; C5; C7; T3; T4; T6; T10; T11; T12; L2; Sacrum**.**

Tenderness

Left Side

- Thoracic Spine **(decreased 5-10% to mild)**
- Lower Back **(decreased 5-10% to mild-moderate)**
- Cervical Spine (Mild)

Right Side

- Thoracic Spine **(decreased 5-10% to mild)**
- Lower Back **(decreased 5-10% to mild-moderate)**
- Cervical Spine (Mild)

Spasm/Hypertonicity

Left Side

- Cervical Spine (Mild)
- Thoracic Spine (Mild)
- Lower Back (Mild-Moderate)

Right Side

- Cervical Spine (Mild)
- Thoracic Spine (Mild)
- Lower Back (Mild-Moderate)

ASSESSMENT

Stage of Care: Rehabilitative

DIAGNOSES

1. Post-traumatic headache, unspecified, not intractable (G44.309)
2. Sprain of ligaments of cervical spine, initial encounter (S13.4XXA)
3. Sprain of ligaments of thoracic spine, initial encounter (S23.3XXA)
4. Sprain of ligaments of lumbar spine, initial encounter (S33.5XXA)
5. Strain of muscle, fascia and tendon at neck level, initial encounter (S16.1XXA)
6. Strain of muscle and tendon of back wall of thorax, initial encounter (S29.012A)
7. Strain of muscle, fascia and tendon of lower back, initial encounter (S39.012A)
8. Segmental and somatic dysfunction of cervical region (M99.01)
9. Segmental and somatic dysfunction of thoracic region (M99.02)
10. Segmental and somatic dysfunction of lumbar region (M99.03)
11. Cervicalgia (M54.2)
12. Pain in thoracic spine (M54.6)
13. Low back pain, unspecified (M54.50)
14. Muscle spasm of back (M62.830)
15. Sleep deprivation (Z72.820)
16. Person injured in unspecified motor-vehicle accident, traffic, initial encounter (V89.2XXA)

PROGNOSIS

Fair - The patient can expect to have a reduction of their symptom and may require ongoing rehabilitation.

PLAN

Based on subjective and objective data, today's treatment consists of:

- CMT 3-4 Regions (98941) consisting of Instrument adjusting, diversified technique, Thompson technique was provided specifically to C1; C5; C7; T3; T4; T6; T10; T11; T12; L2; Sacrum, to reduce pain reported at initial encounter by 50%.

- Electrical Stimulation (97014) consisting of interferential was provided specifically to , to reduce pain reported at initial encounter by 50%.
- Mechanical Traction (97012) consisting of intersegmental traction was provided specifically to , to reduce pain reported at initial encounter by 50%.
- Ice/Heat (97010) consisting of hot pack was provided specifically to , to reduce pain reported at initial encounter by 50%.

Patient received care without incident.



(Electronic Signature)
Provider Name: Mary Dearborn, DC
Date: 10/29/2024 12:05 PM

Iceberg Health Morrow
1544 Southlake Pkwy
Unit 9F
Morrow, GA 30260-0287
(678) 505-0000

*Changes since previous Note have been **formatted differently.***

Daily Note

Patient Name: Anthony Alexander, Jr
Date of Birth: 6/5/1995

Provider: Mary Dearborn, DC
Date of Service: 11/21/2024

SUBJECTIVE

PRIMARY COMPLAINT
Head

- Throbbing, Sharp pain: 2/10
  Described as occasional (up to 25% of day) of minimal to slight intensity (symptom is not alleviated by any amount of modification to ADL); increased by working, changing positions and ADL's; decreased by Prescribed Pain Medication.

SECOND COMPLAINT
Neck

- Sharp pain: 3/10
  Described as occasional (up to 25% of day) of slight intensity (requires some modification to ADL); increased by sleeping, standing, sitting, lifting, walking, running, bending, working, driving, changing positions and ADL's; decreased by Prescribed Pain Medication.

THIRD COMPLAINT
Mid back

- Sharp pain: 3/10
  Described as intermittent (up to 50% of day) of slight to moderate intensity; increased by sleeping, standing, sitting, lifting, walking, running, bending, working, driving, changing positions and ADL's; decreased by rest.

FOURTH COMPLAINT
Low back

- Sharp pain: 4/10
  Described as intermittent (up to 50% of day) of moderate intensity (requires significant or complete modification to ADL); increased by sleeping, standing, sitting, lifting, walking, running, bending, working, driving, changing positions and ADL's; decreased by rest.

Says he feels **okay today**.

OBJECTIVE

PALPATORY FINDINGS

Spinal asymmetry/fixation: C1; C5; C7; T3; T4; T6; T10; T11; T12; L2; Sacrum.

Tenderness

Left Side

- Cervical Spine (Mild)
- Thoracic Spine (Mild)
- Lower Back (Mild-Moderate)

Right Side

- Cervical Spine (Mild)
- Thoracic Spine (Mild)
- Lower Back (Mild-Moderate)

Spasm/Hypertonicity

Left Side

- Cervical Spine (Mild)
- Thoracic Spine (Mild)
- Lower Back (Mild-Moderate)

Right Side

- Cervical Spine (Mild)
- Thoracic Spine (Mild)
- Lower Back (Mild-Moderate)

ASSESSMENT

Stage of Care: Rehabilitative

DIAGNOSES

1. Post-traumatic headache, unspecified, not intractable (G44.309)
2. Sprain of ligaments of cervical spine, initial encounter (S13.4XXA)
3. Sprain of ligaments of thoracic spine, initial encounter (S23.3XXA)
4. Sprain of ligaments of lumbar spine, initial encounter (S33.5XXA)
5. Strain of muscle, fascia and tendon at neck level, initial encounter (S16.1XXA)
6. Strain of muscle and tendon of back wall of thorax, initial encounter (S29.012A)
7. Strain of muscle, fascia and tendon of lower back, initial encounter (S39.012A)
8. Segmental and somatic dysfunction of cervical region (M99.01)
9. Segmental and somatic dysfunction of thoracic region (M99.02)
10. Segmental and somatic dysfunction of lumbar region (M99.03)
11. Cervicalgia (M54.2)
12. Pain in thoracic spine (M54.6)
13. Low back pain, unspecified (M54.50)
14. Muscle spasm of back (M62.830)
15. Sleep deprivation (Z72.820)
16. Person injured in unspecified motor-vehicle accident, traffic, initial encounter (V89.2XXA)

PROGNOSIS

Fair - The patient can expect to have a reduction of their symptom and may require ongoing rehabilitation.

PLAN

Based on subjective and objective data, today's treatment consists of:

- CMT 3-4 Regions (98941) consisting of Instrument adjusting, diversified technique, Thompson technique was provided specifically to C1; C5; C7; T3; T4; T6; T10; T11; T12; L2; Sacrum, to reduce pain reported at initial encounter by 50%.
- Electrical Stimulation (97014) consisting of interferential was provided specifically to , to reduce pain reported at initial encounter by 50%.

- Mechanical Traction (97012) consisting of intersegmental traction was provided specifically to , to reduce pain reported at initial encounter by 50%.
- Ice/Heat (97010) consisting of hot pack was provided specifically to , to reduce pain reported at initial encounter by 50%.

Patient received care without incident.



(Electronic Signature)
Provider Name: Mary Dearborn, DC
Date: 11/21/2024 03:28 PM

Iceberg Health Morrow
1544 Southlake Pkwy
Unit 9F
Morrow, GA 30260-0287
(678) 505-0000

*Changes since previous Note have been **formatted differently.***

Daily Note

Patient Name: Anthony Alexander, Jr
Date of Birth: 6/5/1995

Provider: Mary Dearborn, DC
Date of Service: 11/22/2024

SUBJECTIVE

PRIMARY COMPLAINT
Head

- Throbbing, Sharp pain: 2/10
  Described as occasional (up to 25% of day) of minimal to slight intensity (symptom is not alleviated by any amount of modification to ADL); increased by working, changing positions and ADL's; decreased by Prescribed Pain Medication.

SECOND COMPLAINT
Neck

- Sharp pain: 3/10
  Described as occasional (up to 25% of day) of slight intensity (requires some modification to ADL); increased by sleeping, standing, sitting, lifting, walking, running, bending, working, driving, changing positions and ADL's; decreased by Prescribed Pain Medication.

THIRD COMPLAINT
Mid back

- Sharp pain: 3/10
  Described as intermittent (up to 50% of day) of slight to moderate intensity; increased by sleeping, standing, sitting, lifting, walking, running, bending, working, driving, changing positions and ADL's; decreased by rest.

FOURTH COMPLAINT
Low back

- Sharp pain: 4/10
  Described as intermittent (up to 50% of day) of moderate intensity (requires significant or complete modification to ADL); increased by sleeping, standing, sitting, lifting, walking, running, bending, working, driving, changing positions and ADL's; decreased by rest.

Says he feels okay today.

OBJECTIVE

PALPATORY FINDINGS

Spinal asymmetry/fixation: C1; C5; C7; T3; T4; T6; T10; T11; T12; L2; Sacrum.

Tenderness

Left Side

- Cervical Spine (Mild)
- Thoracic Spine (Mild)
- Lower Back (Mild-Moderate)

Right Side

- Cervical Spine (Mild)
- Thoracic Spine (Mild)
- Lower Back (Mild-Moderate)

Spasm/Hypertonicity

Left Side

- Cervical Spine (Mild)
- Thoracic Spine (Mild)
- Lower Back (Mild-Moderate)

Right Side

- Cervical Spine (Mild)
- Thoracic Spine (Mild)
- Lower Back (Mild-Moderate)

ASSESSMENT

Stage of Care: Rehabilitative

DIAGNOSES

1. Post-traumatic headache, unspecified, not intractable (G44.309)
2. Sprain of ligaments of cervical spine, initial encounter (S13.4XXA)
3. Sprain of ligaments of thoracic spine, initial encounter (S23.3XXA)
4. Sprain of ligaments of lumbar spine, initial encounter (S33.5XXA)
5. Strain of muscle, fascia and tendon at neck level, initial encounter (S16.1XXA)
6. Strain of muscle and tendon of back wall of thorax, initial encounter (S29.012A)
7. Strain of muscle, fascia and tendon of lower back, initial encounter (S39.012A)
8. Segmental and somatic dysfunction of cervical region (M99.01)
9. Segmental and somatic dysfunction of thoracic region (M99.02)
10. Segmental and somatic dysfunction of lumbar region (M99.03)
11. Cervicalgia (M54.2)
12. Pain in thoracic spine (M54.6)
13. Low back pain, unspecified (M54.50)
14. Muscle spasm of back (M62.830)
15. Sleep deprivation (Z72.820)
16. Person injured in unspecified motor-vehicle accident, traffic, initial encounter (V89.2XXA)

PROGNOSIS

Fair - The patient can expect to have a reduction of their symptom and may require ongoing rehabilitation.

PLAN

Based on subjective and objective data, today's treatment consists of:

- CMT 3-4 Regions (98941) consisting of Instrument adjusting, diversified technique, Thompson technique was provided specifically to C1; C5; C7; T3; T4; T6; T10; T11; T12; L2; Sacrum, to reduce pain reported at initial encounter by 50%.
- Electrical Stimulation (97014) consisting of interferential was provided specifically to , to reduce pain reported at initial encounter by 50%.

- Mechanical Traction (97012) consisting of intersegmental traction was provided specifically to , to reduce pain reported at initial encounter by 50%.
- Ice/Heat (97010) consisting of hot pack was provided specifically to , to reduce pain reported at initial encounter by 50%.

Patient received care without incident.



(Electronic Signature)
Provider Name: Mary Dearborn, DC
Date: 11/22/2024 03:29 PM

Iceberg Health Morrow
1544 Southlake Pkwy
Unit 9F
Morrow, GA 30260-0287
(678) 505-0000

*Changes since previous Note have been **formatted differently.***

Daily Note

Patient Name: Anthony Alexander, Jr
Date of Birth: 6/5/1995

Provider: Mary Dearborn, DC
Date of Service: 11/23/2024

SUBJECTIVE

PRIMARY COMPLAINT
Head

- Throbbing, Sharp pain: 2/10
  Described as occasional (up to 25% of day) of minimal to slight intensity (symptom is not alleviated by any amount of modification to ADL); increased by working, changing positions and ADL's; decreased by Prescribed Pain Medication.

SECOND COMPLAINT
Neck

- Sharp pain: 3/10
  Described as occasional (up to 25% of day) of slight intensity (requires some modification to ADL); increased by sleeping, standing, sitting, lifting, walking, running, bending, working, driving, changing positions and ADL's; decreased by Prescribed Pain Medication.

THIRD COMPLAINT
Mid back

- Sharp pain: 3/10
  Described as **occasional to intermittent (up to between 25% and 50% of day)** of slight to moderate intensity; increased by sleeping, standing, sitting, lifting, walking, running, bending, working, driving, changing positions and ADL's; decreased by rest.

FOURTH COMPLAINT
Low back

- Sharp pain: **From 4 to 3/10 (10% decrease)**
  Described as intermittent (up to 50% of day) of **slight to moderate intensity**; increased by sleeping, standing, sitting, lifting, walking, running, bending, working, driving, changing positions and ADL's; decreased by rest.

Says he feels **"good"** today.

OBJECTIVE

PALPATORY FINDINGS
Spinal asymmetry/fixation: C1; C5; C7; T3; T4; T6; T10; T11; T12; L2; Sacrum**.**

Tenderness

Left Side

- Cervical Spine (Mild)
- Thoracic Spine (Mild)
- Lower Back (Mild-Moderate)

Right Side

- Cervical Spine (Mild)
- Thoracic Spine (Mild)
- Lower Back (Mild-Moderate)

Spasm/Hypertonicity

Left Side

- Cervical Spine (Mild)
- Thoracic Spine (Mild)
- Lower Back (Mild-Moderate)

Right Side

- Cervical Spine (Mild)
- Thoracic Spine (Mild)
- Lower Back (Mild-Moderate)

ASSESSMENT

Stage of Care: Rehabilitative

DIAGNOSES

1. Post-traumatic headache, unspecified, not intractable (G44.309)
2. Sprain of ligaments of cervical spine, initial encounter (S13.4XXA)
3. Sprain of ligaments of thoracic spine, initial encounter (S23.3XXA)
4. Sprain of ligaments of lumbar spine, initial encounter (S33.5XXA)
5. Strain of muscle, fascia and tendon at neck level, initial encounter (S16.1XXA)
6. Strain of muscle and tendon of back wall of thorax, initial encounter (S29.012A)
7. Strain of muscle, fascia and tendon of lower back, initial encounter (S39.012A)
8. Segmental and somatic dysfunction of cervical region (M99.01)
9. Segmental and somatic dysfunction of thoracic region (M99.02)
10. Segmental and somatic dysfunction of lumbar region (M99.03)
11. Cervicalgia (M54.2)
12. Pain in thoracic spine (M54.6)
13. Low back pain, unspecified (M54.50)
14. Muscle spasm of back (M62.830)
15. Sleep deprivation (Z72.820)
16. Person injured in unspecified motor-vehicle accident, traffic, initial encounter (V89.2XXA)

PROGNOSIS

Fair - The patient can expect to have a reduction of their symptom and may require ongoing rehabilitation.

PLAN

Based on subjective and objective data, today's treatment consists of:

- CMT 3-4 Regions (98941) consisting of Instrument adjusting, diversified technique, Thompson technique was provided specifically to C1; C5; C7; T3; T4; T6; T10; T11; T12; L2; Sacrum, to reduce pain reported at initial encounter by 50%.
- Electrical Stimulation (97014) consisting of interferential was provided specifically to , to reduce pain reported at initial encounter by 50%.
- Mechanical Traction (97012) consisting of intersegmental traction was provided specifically to , to reduce pain reported at initial encounter by 50%.
- Ice/Heat (97010) consisting of hot pack was provided specifically to , to reduce pain

reported at initial encounter by 50%.

Patient received care without incident.



(Electronic Signature)
Provider Name: Mary Dearborn, DC
Date: 11/23/2024 09:24 AM

Iceberg Health Morrow
1544 Southlake Pkwy
Unit 9F
Morrow, GA 30260-0287
(678) 505-0000

*Changes since previous Note have been **formatted differently.***

Daily Note

Patient Name: Anthony Alexander, Jr
Date of Birth: 6/5/1995

Provider: Amanda Ruiz, DC
Date of Service: 11/25/2024

SUBJECTIVE

PRIMARY COMPLAINT
Head

- Throbbing, Sharp pain: 2/10
  Described as occasional (up to 25% of day) of minimal to slight intensity (symptom is not alleviated by any amount of modification to ADL); increased by working, changing positions and ADL's; decreased by Prescribed Pain Medication.

SECOND COMPLAINT
Neck

- Sharp pain: 3/10
  Described as occasional (up to 25% of day) of slight intensity (requires some modification to ADL); increased by sleeping, standing, sitting, lifting, walking, running, bending, working, driving, changing positions and ADL's; decreased by Prescribed Pain Medication.

THIRD COMPLAINT
Mid back

- Sharp pain: 3/10
  Described as occasional to intermittent (up to between 25% and 50% of day) of slight to moderate intensity; increased by sleeping, standing, sitting, lifting, walking, running, bending, working, driving, changing positions and ADL's; decreased by rest.

FOURTH COMPLAINT
Low back

- Sharp pain: 3/10
  Described as intermittent (up to 50% of day) of slight to moderate intensity; increased by sleeping, standing, sitting, lifting, walking, running, bending, working, driving, changing positions and ADL's; decreased by rest.

OBJECTIVE

PALPATORY FINDINGS
Spinal asymmetry/fixation: C1; C5; C7; T3; T4; T6; T10; T11; T12; L2; Sacrum.

Tenderness

Left Side

- Cervical Spine (Mild)
- Thoracic Spine (Mild)
- Lower Back (Mild-Moderate)

Right Side

- Cervical Spine (Mild)
- Thoracic Spine (Mild)
- Lower Back (Mild-Moderate)

Spasm/Hypertonicity

Left Side

- Cervical Spine (Mild)
- Thoracic Spine (Mild)
- Lower Back (Mild-Moderate)

Right Side

- Cervical Spine (Mild)
- Thoracic Spine (Mild)
- Lower Back (Mild-Moderate)

ASSESSMENT

Stage of Care: Rehabilitative

DIAGNOSES

1. Post-traumatic headache, unspecified, not intractable (G44.309)
2. Sprain of ligaments of cervical spine, initial encounter (S13.4XXA)
3. Sprain of ligaments of thoracic spine, initial encounter (S23.3XXA)
4. Sprain of ligaments of lumbar spine, initial encounter (S33.5XXA)
5. Strain of muscle, fascia and tendon at neck level, initial encounter (S16.1XXA)
6. Strain of muscle and tendon of back wall of thorax, initial encounter (S29.012A)
7. Strain of muscle, fascia and tendon of lower back, initial encounter (S39.012A)
8. Segmental and somatic dysfunction of cervical region (M99.01)
9. Segmental and somatic dysfunction of thoracic region (M99.02)
10. Segmental and somatic dysfunction of lumbar region (M99.03)
11. Cervicalgia (M54.2)
12. Pain in thoracic spine (M54.6)
13. Low back pain, unspecified (M54.50)
14. Muscle spasm of back (M62.830)
15. Sleep deprivation (Z72.820)
16. Person injured in unspecified motor-vehicle accident, traffic, initial encounter (V89.2XXA)

PROGNOSIS

Fair - The patient can expect to have a reduction of their symptom and may require ongoing rehabilitation.

PLAN

Based on subjective and objective data, today's treatment consists of:

- CMT 3-4 Regions (98941) consisting of Instrument adjusting, diversified technique, Thompson technique was provided specifically to C1; C5; C7; T3; T4; T6; T10; T11; T12; L2; **Pelvis**, to reduce pain reported at initial encounter by 50%.
- Electrical Stimulation (97014) consisting of interferential was provided specifically to , to reduce pain reported at initial encounter by 50%.
- Mechanical Traction (97012) consisting of intersegmental traction was provided specifically to , to reduce pain reported at initial encounter by 50%.
- Ice/Heat (97010) consisting of hot pack was provided specifically to , to reduce pain

reported at initial encounter by 50%.

Patient received care without incident.

(Electronic Signature)
Provider Name: Amanda Ruiz, DC
Date: 11/25/2024 03:29 PM

Iceberg Health Morrow
1544 Southlake Pkwy
Unit 9F
Morrow, GA 30260-0287
(678) 505-0000

*Changes since previous Note have been **formatted differently.***

Daily Note

Patient Name: Anthony Alexander, Jr
Date of Birth: 6/5/1995

Provider: Amanda Ruiz, DC
Date of Service: 11/26/2024

SUBJECTIVE

PRIMARY COMPLAINT
Head

- Throbbing, Sharp pain: 2/10
  Described as occasional (up to 25% of day) of minimal to slight intensity (symptom is not alleviated by any amount of modification to ADL); increased by working, changing positions and ADL's; decreased by Prescribed Pain Medication.

SECOND COMPLAINT
Neck

- Sharp pain: 3/10
  Described as occasional (up to 25% of day) of slight intensity (requires some modification to ADL); increased by sleeping, standing, sitting, lifting, walking, running, bending, working, driving, changing positions and ADL's; decreased by Prescribed Pain Medication.

THIRD COMPLAINT
Mid back

- Sharp pain: 3/10
  Described as occasional to intermittent (up to between 25% and 50% of day) of slight to moderate intensity; increased by sleeping, standing, sitting, lifting, walking, running, bending, working, driving, changing positions and ADL's; decreased by rest.

FOURTH COMPLAINT
Low back

- Sharp pain: 3/10
  Described as intermittent (up to 50% of day) of slight to moderate intensity; increased by sleeping, standing, sitting, lifting, walking, running, bending, working, driving, changing positions and ADL's; decreased by rest.

OBJECTIVE

PALPATORY FINDINGS
Spinal asymmetry/fixation: C1; C5; C7; T3; T4; T6; T10; T11; T12; L2; Sacrum.

Tenderness

Left Side

- Cervical Spine (Mild)
- Thoracic Spine (Mild)
- Lower Back (Mild-Moderate)

Right Side

- Cervical Spine (Mild)
- Thoracic Spine (Mild)
- Lower Back (Mild-Moderate)

Spasm/Hypertonicity

Left Side

- Cervical Spine (Mild)
- Thoracic Spine (Mild)
- Lower Back (Mild-Moderate)

Right Side

- Cervical Spine (Mild)
- Thoracic Spine (Mild)
- Lower Back (Mild-Moderate)

ASSESSMENT

Stage of Care: Rehabilitative

DIAGNOSES

1. Post-traumatic headache, unspecified, not intractable (G44.309)
2. Sprain of ligaments of cervical spine, initial encounter (S13.4XXA)
3. Sprain of ligaments of thoracic spine, initial encounter (S23.3XXA)
4. Sprain of ligaments of lumbar spine, initial encounter (S33.5XXA)
5. Strain of muscle, fascia and tendon at neck level, initial encounter (S16.1XXA)
6. Strain of muscle and tendon of back wall of thorax, initial encounter (S29.012A)
7. Strain of muscle, fascia and tendon of lower back, initial encounter (S39.012A)
8. Segmental and somatic dysfunction of cervical region (M99.01)
9. Segmental and somatic dysfunction of thoracic region (M99.02)
10. Segmental and somatic dysfunction of lumbar region (M99.03)
11. Cervicalgia (M54.2)
12. Pain in thoracic spine (M54.6)
13. Low back pain, unspecified (M54.50)
14. Muscle spasm of back (M62.830)
15. Sleep deprivation (Z72.820)
16. Person injured in unspecified motor-vehicle accident, traffic, initial encounter (V89.2XXA)

PROGNOSIS

Fair - The patient can expect to have a reduction of their symptom and may require ongoing rehabilitation.

PLAN

Based on subjective and objective data, today's treatment consists of:

- CMT 3-4 Regions (98941) consisting of Instrument adjusting, diversified technique, Thompson technique was provided specifically to C1; C5; C7; T3; T4; T6; T10; T11; T12; L2; Pelvis, to reduce pain reported at initial encounter by 50%.
- Electrical Stimulation (97014) consisting of interferential was provided specifically to , to reduce pain reported at initial encounter by 50%.
- Mechanical Traction (97012) consisting of intersegmental traction was provided specifically to , to reduce pain reported at initial encounter by 50%.
- Ice/Heat (97010) consisting of hot pack was provided specifically to , to reduce pain

reported at initial encounter by 50%.

Patient received care without incident.

(Electronic Signature)
Provider Name: Amanda Ruiz, DC
Date: 11/26/2024 04:02 PM

Iceberg Health Morrow
1544 Southlake Pkwy
Unit 9F
Morrow, GA 30260-0287
(678) 505-0000

*Changes since previous Note have been **formatted differently.***

Daily Note

Patient Name: Anthony Alexander, Jr
Date of Birth: 6/5/1995

Provider: Amanda Ruiz, DC
Date of Service: 11/30/2024

SUBJECTIVE

PRIMARY COMPLAINT
Head

- Throbbing, Sharp pain: 2/10
  Described as occasional (up to 25% of day) of minimal to slight intensity (symptom is not alleviated by any amount of modification to ADL); increased by working, changing positions and ADL's; decreased by Prescribed Pain Medication.

SECOND COMPLAINT
Neck

- Sharp pain: 3/10
  Described as occasional (up to 25% of day) of slight intensity (requires some modification to ADL); increased by sleeping, standing, sitting, lifting, walking, running, bending, working, driving, changing positions and ADL's; decreased by Prescribed Pain Medication.

THIRD COMPLAINT
Mid back

- Sharp pain: 3/10
  Described as occasional to intermittent (up to between 25% and 50% of day) of slight to moderate intensity; increased by sleeping, standing, sitting, lifting, walking, running, bending, working, driving, changing positions and ADL's; decreased by rest.

FOURTH COMPLAINT
Low back

- Sharp pain: 3/10
  Described as intermittent (up to 50% of day) of slight to moderate intensity; increased by sleeping, standing, sitting, lifting, walking, running, bending, working, driving, changing positions and ADL's; decreased by rest.

OBJECTIVE

PALPATORY FINDINGS
Spinal asymmetry/fixation: C1; C5; C7; T3; T4; T6; T10; T11; T12; L2; Sacrum.

Tenderness

Left Side

- Cervical Spine (Mild)
- Thoracic Spine (Mild)
- Lower Back (Mild-Moderate)

Right Side

- Cervical Spine (Mild)
- Thoracic Spine (Mild)
- Lower Back (Mild-Moderate)

Spasm/Hypertonicity

Left Side

- Cervical Spine (Mild)
- Thoracic Spine (Mild)
- Lower Back (Mild-Moderate)

Right Side

- Cervical Spine (Mild)
- Thoracic Spine (Mild)
- Lower Back (Mild-Moderate)

ASSESSMENT

Stage of Care: Rehabilitative

DIAGNOSES

1. Post-traumatic headache, unspecified, not intractable (G44.309)
2. Sprain of ligaments of cervical spine, initial encounter (S13.4XXA)
3. Sprain of ligaments of thoracic spine, initial encounter (S23.3XXA)
4. Sprain of ligaments of lumbar spine, initial encounter (S33.5XXA)
5. Strain of muscle, fascia and tendon at neck level, initial encounter (S16.1XXA)
6. Strain of muscle and tendon of back wall of thorax, initial encounter (S29.012A)
7. Strain of muscle, fascia and tendon of lower back, initial encounter (S39.012A)
8. Segmental and somatic dysfunction of cervical region (M99.01)
9. Segmental and somatic dysfunction of thoracic region (M99.02)
10. Segmental and somatic dysfunction of lumbar region (M99.03)
11. Cervicalgia (M54.2)
12. Pain in thoracic spine (M54.6)
13. Low back pain, unspecified (M54.50)
14. Muscle spasm of back (M62.830)
15. Sleep deprivation (Z72.820)
16. Person injured in unspecified motor-vehicle accident, traffic, initial encounter (V89.2XXA)

PROGNOSIS

Fair - The patient can expect to have a reduction of their symptom and may require ongoing rehabilitation.

PLAN

Based on subjective and objective data, today's treatment consists of:

- CMT 3-4 Regions (98941) consisting of Instrument adjusting, diversified technique, Thompson technique was provided specifically to C1; C5; C7; T3; T4; T6; T10; T11; T12; L2; Pelvis, to reduce pain reported at initial encounter by 50%.
- Electrical Stimulation (97014) consisting of interferential was provided specifically to , to reduce pain reported at initial encounter by 50%.
- Mechanical Traction (97012) consisting of intersegmental traction was provided specifically to , to reduce pain reported at initial encounter by 50%.
- Ice/Heat (97010) consisting of hot pack was provided specifically to , to reduce pain

reported at initial encounter by 50%.

Patient received care without incident.

(Electronic Signature)
Provider Name: Amanda Ruiz, DC
Date: 11/30/2024 10:17 AM

Iceberg Health Morrow
1544 Southlake Pkwy
Unit 9F
Morrow, GA 30260-0287
(678) 505-0000

*Changes since previous Note have been **formatted differently.***

Daily Note

Patient Name: Anthony Alexander, Jr
Date of Birth: 6/5/1995

Provider: Amanda Ruiz, DC
Date of Service: 12/2/2024

SUBJECTIVE

PRIMARY COMPLAINT
Head

- Throbbing, Sharp pain: 2/10
  Described as occasional (up to 25% of day) of minimal to slight intensity (symptom is not alleviated by any amount of modification to ADL); increased by working, changing positions and ADL's; decreased by Prescribed Pain Medication.

SECOND COMPLAINT
Neck

- Sharp pain: 3/10
  Described as occasional (up to 25% of day) of slight intensity (requires some modification to ADL); increased by sleeping, standing, sitting, lifting, walking, running, bending, working, driving, changing positions and ADL's; decreased by Prescribed Pain Medication.

THIRD COMPLAINT
Mid back

- Sharp pain: 3/10
  Described as occasional to intermittent (up to between 25% and 50% of day) of slight to moderate intensity; increased by sleeping, standing, sitting, lifting, walking, running, bending, working, driving, changing positions and ADL's; decreased by rest.

FOURTH COMPLAINT
Low back

- Sharp pain: 3/10
  Described as intermittent (up to 50% of day) of slight to moderate intensity; increased by sleeping, standing, sitting, lifting, walking, running, bending, working, driving, changing positions and ADL's; decreased by rest.

OBJECTIVE

PALPATORY FINDINGS
Spinal asymmetry/fixation: C1; C5; C7; T3; T4; T6; T10; T11; T12; L2; Sacrum.

Tenderness

Left Side

- Cervical Spine (Mild)
- Thoracic Spine (Mild)
- Lower Back (Mild-Moderate)

Right Side

- Cervical Spine (Mild)
- Thoracic Spine (Mild)
- Lower Back (Mild-Moderate)

Spasm/Hypertonicity

Left Side

- Cervical Spine (Mild)
- Thoracic Spine (Mild)
- Lower Back (Mild-Moderate)

Right Side

- Cervical Spine (Mild)
- Thoracic Spine (Mild)
- Lower Back (Mild-Moderate)

ASSESSMENT

Stage of Care: Rehabilitative

DIAGNOSES

1. Post-traumatic headache, unspecified, not intractable (G44.309)
2. Sprain of ligaments of cervical spine, initial encounter (S13.4XXA)
3. Sprain of ligaments of thoracic spine, initial encounter (S23.3XXA)
4. Sprain of ligaments of lumbar spine, initial encounter (S33.5XXA)
5. Strain of muscle, fascia and tendon at neck level, initial encounter (S16.1XXA)
6. Strain of muscle and tendon of back wall of thorax, initial encounter (S29.012A)
7. Strain of muscle, fascia and tendon of lower back, initial encounter (S39.012A)
8. Segmental and somatic dysfunction of cervical region (M99.01)
9. Segmental and somatic dysfunction of thoracic region (M99.02)
10. Segmental and somatic dysfunction of lumbar region (M99.03)
11. Cervicalgia (M54.2)
12. Pain in thoracic spine (M54.6)
13. Low back pain, unspecified (M54.50)
14. Muscle spasm of back (M62.830)
15. Sleep deprivation (Z72.820)
16. Person injured in unspecified motor-vehicle accident, traffic, initial encounter (V89.2XXA)

PROGNOSIS

Fair - The patient can expect to have a reduction of their symptom and may require ongoing rehabilitation.

PLAN

Based on subjective and objective data, today's treatment consists of:

- CMT 3-4 Regions (98941) consisting of Instrument adjusting, diversified technique, Thompson technique was provided specifically to C1; C5; C7; T3; T4; T6; T10; T11; T12; L2; Pelvis, to reduce pain reported at initial encounter by 50%.
- Electrical Stimulation (97014) consisting of interferential was provided specifically to , to reduce pain reported at initial encounter by 50%.
- Mechanical Traction (97012) consisting of intersegmental traction was provided specifically to , to reduce pain reported at initial encounter by 50%.
- Ice/Heat (97010) consisting of hot pack was provided specifically to , to reduce pain

reported at initial encounter by 50%.

Patient received care without incident.

(Electronic Signature)
Provider Name: Amanda Ruiz, DC
Date: 12/02/2024 03:27 PM

Iceberg Health Morrow
1544 Southlake Pkwy
Unit 9F
Morrow, GA 30260-0287
(678) 505-0000

*Changes since previous Note have been **formatted differently.***

Exam

Patient Name: Anthony Alexander, Jr
Date of Birth: 6/5/1995

Provider: Mary Dearborn, DC
Date of Service: 12/3/2024

SUBJECTIVE

PRIMARY COMPLAINT
Head

- Throbbing, Sharp pain: 2/10
  Described as occasional (up to 25% of day) of minimal to slight intensity (symptom is not alleviated by any amount of modification to ADL); increased by working, changing positions and ADL's; decreased by Prescribed Pain Medication.

SECOND COMPLAINT
Neck

- Sharp pain: 3/10
  Described as occasional (up to 25% of day) of slight intensity (requires some modification to ADL); increased by sleeping, standing, sitting, lifting, walking, running, bending, working, driving, changing positions and ADL's; decreased by Prescribed Pain Medication.

THIRD COMPLAINT
Mid back

- Sharp pain: 3/10
  Described as occasional to intermittent (up to between 25% and 50% of day) of slight to moderate intensity; increased by sleeping, standing, sitting, lifting, walking, running, bending, working, driving, changing positions and ADL's; decreased by rest.

FOURTH COMPLAINT
Low back

- Sharp pain: 3/10
  Described as intermittent (up to 50% of day) of slight to moderate intensity; increased by sleeping, standing, sitting, lifting, walking, running, bending, working, driving, changing positions and ADL's; decreased by rest.

States that he feels he has improved.

OBJECTIVE

VITALS
Height: 69” in
Pulse rate: 67 BPM (relaxed)
Blood Pressure (seated): right -N/A left-135/75 mmHg

PALPATORY FINDINGS
Spinal asymmetry/fixation: C1; C5; C7; T3; T4; T6; T10; T11; T12; L2; Sacrum.

Tenderness

Left Side

- Lower Back **(decreased 5-10% to mild)**
- Cervical Spine (Mild)
- Thoracic Spine (Mild)

Right Side

- Lower Back **(decreased 5-10% to mild)**
- Cervical Spine (Mild)
- Thoracic Spine (Mild)

Spasm/Hypertonicity

Left Side

- Lower Back **(decreased 5-10% to mild)**
- Cervical Spine (Mild)
- Thoracic Spine (Mild)

Right Side

- Lower Back **(decreased 5-10% to mild)**
- Cervical Spine (Mild)
- Thoracic Spine (Mild)

GAIT

Ambulation: Normal.
Gait: Normal.

ORTHOPEDIC AND NEUROLOGICAL TESTS

Test	Left	Right	Comment
Shoulder depression test[1]	Positive	WNL	
Spinal percussion test-thoracic[2]	Positive	Positive	
Kemp's test[3]	Positive	WNL	
Straight leg raise[4]	Positive	WNL	

[1]Pain in the arm could indicate adhesions of the nerve roots. Local pain could indicate sprain or strain or adhesions of the shoulder joint capsule.

[2]Localized pain suggests possible vertebral fracture. Radicular pain indicates possible disc lesion.

[3]Perhipheral pain in to the lower extremities indicates nerve root compression. Local pain may indicate sprain or strain.

[4]Perhipheral pain is suggestive of nerve root irritation, such as that due to a herniated disc.

Cervical distraction , **Foraminal compression test**, **Spinal percussion test-cervical**, **Schepelmann's sign** and **Bragard's test** are within normal limits.

REFLEXES

Biceps, Tricep, Brachioradialis, Patellar and Achilles are within normal limits bilaterally.

RANGE OF MOTION

Cervical ROM - estimated

Test	Measurement	Limited By	Comment
Extension	**55° (91% of normal, increased by 10%)**	Pain, Spasm	
Left lateral flexion	**40° (88% of normal, increased by 14%)**	Pain	
Right lateral flexion	**40° (88% of normal, increased by 14%)**	Pain	
Left rotation	**70° (87% of normal, increased by 7%)**	Pain	
Right rotation	**75° (93% of normal, increased by 7%)**	Pain	

Flexion within normal limits.

Lumbar ROM - estimated

Test	Measurement	Limited By	Comment
Flexion	**55° (91% of normal, increased by 10%)**	Pain	

Extension, **Left lateral flexion**, **Right ateral flexion**, **Left rotation** and **Right rotation** are within normal limits.

DERMATOMES

Posterior

Left-Cervical, Right-Cervical, Left-Lumbar and Right-Lumbar are within normal limits.

PHYSICAL EXAMINATION

General [well nourished, no acute distress]: WNL.
Skin [no skin sensitivity reported, free of lesions, rashes, eczema, upper/lower extremities]: WNL.
Head [eyes – symmetric appearance, conjunctiva white, no discharge, erythema, lid lag or swelling]: WNL.
Ears [no discharge or deformities noted to external ears]: WNL.
Nose [no sinus tenderness, epistaxis, or discharge]: WNL.
Oropharynx [lips free of lesions, cyanosis, no halitosis]: WNL.
Neck [supple, thyroroid non-palpable, no enlarged cervical lymph nodes palpable]: WNL.
Extremities – [upper/lower extremities free of edema, cyanosis, varicosities, cellulitis, pedal pulses 2+]: WNL.
Gross musculoskeletal deformities: WNL.

ASSESSMENT

Stage of Care: Rehabilitative

DIAGNOSES

1. Post-traumatic headache, unspecified, not intractable (G44.309)
2. Sprain of ligaments of cervical spine, initial encounter (S13.4XXA)
3. Sprain of ligaments of thoracic spine, initial encounter (S23.3XXA)
4. Sprain of ligaments of lumbar spine, initial encounter (S33.5XXA)
5. Strain of muscle, fascia and tendon at neck level, initial encounter (S16.1XXA)
6. Strain of muscle and tendon of back wall of thorax, initial encounter (S29.012A)
7. Strain of muscle, fascia and tendon of lower back, initial encounter (S39.012A)
8. Segmental and somatic dysfunction of cervical region (M99.01)
9. Segmental and somatic dysfunction of thoracic region (M99.02)
10. Segmental and somatic dysfunction of lumbar region (M99.03)
11. Cervicalgia (M54.2)
12. Pain in thoracic spine (M54.6)
13. Low back pain, unspecified (M54.50)
14. Muscle spasm of back (M62.830)
15. Sleep deprivation (Z72.820)
16. Person injured in unspecified motor-vehicle accident, traffic, initial encounter (V89.2XXA)

PROGNOSIS

Fair - The patient can expect to have a reduction of their symptom and may require ongoing rehabilitation.

LONG-TERM GOALS

- Decrease pain to pre-injury status: **Progressed from 0% to 40% of goal achieved.**

Patient is **showing improvement** since the prior visit, He is **progressing as anticipated**.

PLAN

Based on subjective and objective data, today's treatment consists of:

- CMT 3-4 Regions (98941) consisting of Instrument adjusting, diversified technique, Thompson technique was provided specifically to C1; C5; C7; T3; T4; T6; T10; T11; T12; L2; **Sacrum**, to reduce pain reported at initial encounter by 50%.
- Electrical Stimulation (97014) consisting of interferential was provided specifically to , to reduce pain reported at initial encounter by 50%.
- Mechanical Traction (97012) consisting of intersegmental traction was provided specifically to , to reduce pain reported at initial encounter by 50%.
- Ice/Heat (97010) consisting of hot pack was provided specifically to , to reduce pain reported at initial encounter by 50%.
- **Established Patient evaluation and management service, 99213, was provided today.**

Final exam today. The patient will continue with home care instructions if symptoms persist. The patient has future office visits with other healthcare providers related to this MVC and will follow recommendations for any continued care.

Patient received care without incident.



(Electronic Signature)
Provider Name: Mary Dearborn, DC
Date: 12/03/2024 03:48 PM

Addenda

The patient is being discharged today after a course of care with residual deficits in function from the injuries sustained from their Motor Vehicle Accident.
According to the American Medical Association (AMA) Guides to the Evaluation of Permanent Impairment 5th edition this patient may have a Permanent whole-body impairment of up to 16%.
In order to prevent further damage this patient may have to receive regular treatment at the rate of 2 times per month for life.
Approximate $82,800 in conservative lifetime treatment costs.

Lifetime Treatment Costs = [Avg. Life expectancy - Current Age] X 12 X $150= Lifetime treatment.

The average Male Life Expectancy is 75.3 years.
The average Female Life Expectancy is 81.1 years.

Electronic Signature: Dearborn, Mary DC

Added on Dec 03, 2024

CONFIDENTIAL FAX COVER SHEET

DATE: 9/19/2024

ATTN TO: ICEBERG HEALTH

FAX TO #: 470-823-9759

FROM: PAH 5A NEURO ICU
ATTENTION: ROI Department
1968 PEACHTREE RD NW
ATLANTA, GA 30309-1281

DEPT/FACILITY PHONE: 404-605-3535

This message is intended only for the use of the individual or entity to which it is addressed.
These documents may contain confidential information including patient information that is highly sensitive and protected by applicable state and federal law. The authorized recipient of this information is prohibited from disclosing this information to any other party and is required to destroy the information after its stated need has been fulfilled. If you are not the intended recipient, you are hereby notified that any disclosure, copying, distribution or action taken in reliance of the contents of these documents is strictly prohibited by law. If you have received this transmission in error, please notify the sender immediately to arrange for the return or destruction of these documents.

Piedmont HEALTHCARE

Alexander, Anthony Deandre Jr.
MRN: 913387030, DOB: 6/5/1995, Legal Sex: M
Adm: 9/1/2024, D/C: 9/1/2024

Department

Name	Address	Phone	Fax
Piedmont Atlanta Hospital Emergency Department	1968 PEACHTREE RD NW Atlanta GA 30309-1281	404-605-3297	404-367-3579

Patient Demographics

Address	Phone	E-mail Address
3478 LAKESIDE DR NE ATLANTA GA 30326	216-390-9548(Home) 216-390-9548(Mobile)	216ton3@gmail.com

Admission Information

Arrival Date/Time:	09/01/2024 1216	Admit Date/Time:	09/01/2024 1415	IP Adm. Date/Time:	
Admission Type:	Emergency	Point of Origin:	SelfReferral	Admit Category:	
Means of Arrival:	Car	Primary Service:	Emergency Medicine	Secondary Service:	N/A
Transfer Source:		Service Area:	PIEDMONT HEALTHCARE	Unit:	Piedmont Atlanta Hospital Emergency Department
Admit Provider:		Attending Provider:	Gottfrid Jona Karlsson, MD	Referring Provider:	

Providers as of 9/1/2024

PCP

Name	Type	Specialty	Phone Number
Per Patient Nopcp, MD	Not available	Not available	Not available

Care Team

No care team found

Discharge Summaries

No notes of this type exist for this encounter.

Piedmont HEALTHCARE

Alexander, Anthony Deandre Jr.
MRN: 913387030, DOB: 6/5/1995, Legal Sex: M
Adm: 9/1/2024, D/C: 9/1/2024

ED Notes

ED Provider Notes by Gottfrid Jona Karlsson, MD at 9/1/2024 2:21 PM

Author: Gottfrid Jona Karlsson, MD | Service: Emergency Medicine | Author Type: Physician
Filed: 9/1/2024 6:00 PM | Date of Service: 9/1/2024 2:21 PM | Status: Signed
Editor: Gottfrid Jona Karlsson, MD (Physician)

History

The history is provided by the patient. No language interpreter was used.

Time seen by provider: 2:36 PM

Mode of arrival: PV

The patient is a 29 y.o. male with no PMHx who presents to the ED for evaluation of headache since yesterday after being involved in a MVC. Patient also complains of neck and back pain. Patient reports that he was a restrained driver who was rear-ended yesterday at 11:15 PM. Patient notes that he was able to self extricate and walk afterwards. Patient denies airbag deployment. He denies LOC. Patient denies weakness, numbness, or abdominal pain. He denies any allergies or daily medications.

No past medical history on file.

No past surgical history on file.

No family history on file.

Additional Information

Previous Medications

No medications on file

No Known Allergies

Review of Systems
Constitutional: Negative for chills and fever.
HENT: Negative for ear pain and sore throat.
Eyes: Negative for pain and visual disturbance.
Respiratory: Negative for cough and shortness of breath.
Cardiovascular: Negative for chest pain and palpitations.
Gastrointestinal: Negative for abdominal pain and vomiting.
Genitourinary: Negative for dysuria and hematuria.
Musculoskeletal: Positive for back pain and neck pain. Negative for arthralgias.
Skin: Negative for color change and rash.
Neurological: Positive for headaches. Negative for seizures, syncope, weakness and numbness.

ED Notes (continued)

ED Provider Notes by Gottfrid Jona Karlsson, MD at 9/1/2024 2:21 PM (continued)

All other systems reviewed and are negative.

Physical Exam

BP 139/70 | Pulse 63 | Temp 98.6 °F (37 °C) (Oral) | Resp 17 | Ht 5' 9" (1.753 m) | Wt 74.8 kg (165 lb) | SpO2 98% | BMI 24.37 kg/m²

Vital signs reviewed.

Physical Exam

Vitals and nursing note reviewed.

Constitutional:
General: He is not in acute distress.
Appearance: Normal appearance. He is well-developed. He is not ill-appearing or diaphoretic.

HENT:
Head: Normocephalic and atraumatic.
Mouth/Throat:
Pharynx: No oropharyngeal exudate.

Eyes:
General: No scleral icterus.
Extraocular Movements: Extraocular movements intact.
Conjunctiva/sclera: Conjunctivae normal.

Neck:
Vascular: No JVD.

Cardiovascular:
Rate and Rhythm: Normal rate and regular rhythm.
Heart sounds: Normal heart sounds. No murmur heard.
No friction rub. No gallop.

Pulmonary:
Effort: Pulmonary effort is normal. No respiratory distress.
Breath sounds: Normal breath sounds. No wheezing.

Abdominal:
General: There is no distension.
Palpations: Abdomen is soft.
Tenderness: There is no abdominal tenderness. There is no guarding or rebound.

Musculoskeletal:
General: Normal range of motion.
Cervical back: Normal range of motion and neck supple. Tenderness **(mild)** present.
Thoracic back: Tenderness **(mild)** present.
Comments: **No leg swelling**
No calf tenderness
Strong and equal pedal and radial pulses bilaterally.

Lymphadenopathy:
Cervical: No cervical adenopathy.

Skin:
General: Skin is warm and dry.
Findings: No rash.

Neurological:

ED Notes (continued)

ED Provider Notes by Gottfrid Jona Karlsson, MD at 9/1/2024 2:21 PM (continued)

Mental Status: He is alert and oriented to person, place, and time.
Cranial Nerves: No cranial nerve deficit.
Comments: **No obvious neurological deficits**
No ataxia. No facial droop. Strength 5/5 in all extremities
Psychiatric:
Mood and Affect: Mood normal.
Behavior: Behavior normal.

ED Course

Thrombolytic Stroke Assessment

NIH Stroke Assessment Scale

Medical Decision Making

Repeat Vitals:
Vitals:

	09/01/24 1251	09/01/24 1252
BP:		139/70
Pulse:	63	
Resp:	17	
Temp:		98.6 °F (37 °C)
TempSrc:		Oral
SpO2:	98%	
Weight:	74.8 kg (165 lb)	
Height:	5' 9" (1.753 m)	

---------- **MEDICAL DECISION MAKING** ----------

Nursing Notes:
Reviewed and utilized the nursing notes.

ED Notes (continued)

ED Provider Notes by Gottfrid Jona Karlsson, MD at 9/1/2024 2:21 PM (continued)

Old Medical Records:
The patient's available past medical records and past encounters were reviewed.

Laboratory Studies:
Ordered and independently reviewed and interpreted laboratory tests. Abnormal findings are listed below:
Labs Reviewed - No data to display

Imaging Studies:
Imaging studies were ordered. Radiologist's interpretation includes:
CT head without contrast
Final Result
1. No acute intracranial abnormality.
2. No acute fracture or traumatic malalignment of the cervical spine.
3. Bilateral thyroid nodule
4. 2 mm left-sided fissural nodule. According to the Fleischner Society Guidelines for incidentally discovered solid pulmonary nodules (MacMahon et al, Radiology, 2017): For patient's this age, no radiologic follow-up is required for nodules this size in the absence of a known history of malignancy.

Thyroid nodule recommendation:
Nonemergent/outpatient thyroid ultrasound.

Electronically Signed By: Nikhar P Kinger MD
9/1/2024 4:21 PM
PARDGYRDRM005R

CT cervical spine without contrast
Final Result
1. No acute intracranial abnormality.
2. No acute fracture or traumatic malalignment of the cervical spine.
3. Bilateral thyroid nodule
4. 2 mm left-sided fissural nodule. According to the Fleischner Society Guidelines for incidentally discovered solid pulmonary nodules (MacMahon et al, Radiology, 2017): For patient's this age, no

ED Notes (continued)

ED Provider Notes by Gottfrid Jona Karlsson, MD at 9/1/2024 2:21 PM (continued)

radiologic follow-up
is required for nodules this size in the absence of a
known history of
malignancy.

Thyroid nodule recommendation:
Nonemergent/outpatient thyroid
ultrasound.

Electronically Signed By: Nikhar P Kinger MD
9/1/2024 4:21 PM
PARDGYRDRM005R

CT thoracic spine without contrast
Final Result
1. No acute, displaced fracture or traumatic
malalignment of the
thoracic spine.
2. Mild wedging of mid thoracic vertebral bodies
which could reflect
Scheuermann's disease.
3. Bilateral thyroid nodules.. Recommend
nonemergent/outpatient thyroid
ultrasound.

Pulmonary nodule recommendation: Given the
patient?s age, no follow-up
is required.

Electronically Signed By: Nikhar P Kinger MD
9/1/2024 4:34 PM
PARDGYRDRM005R

EKG:
None

Orders:
Orders Placed This Encounter

- CT head without contrast

Standing Status:	Standing
Number of Occurrences:	1
Order Specific Question:	Reason for Exam
Answer:	head trauma and headache

ED Notes (continued)

ED Provider Notes by Gottfrid Jona Karlsson, MD at 9/1/2024 2:21 PM (continued)

- CT cervical spine without contrast
  - Standing Status: Standing
  - Number of Occurrences: 1
  - Order Specific Question: Reason for Exam
  - Answer: midline tenderness after MVC
- CT thoracic spine without contrast
  - Standing Status: Standing
  - Number of Occurrences: 1
  - Order Specific Question: Reason for Exam
  - Answer: pain after MVC
- acetaminophen (TYLENOL) tablet 1,000 mg
- metoclopramide HCl (REGLAN) injection 10 mg
- ketorolac (TORADOL) injection 15 mg
- ibuprofen (MOTRIN) 600 MG tablet
  Sig: Take 1 tablet by mouth every 8 (eight) hours as needed.
  Dispense: 21 tablet
  Refill: 0

Medications given in the ED:

Medication Administration from 09/01/2024 1216 to 09/01/2024 1734

None

---------- **PROGRESS NOTES** ----------

Re-examinations:
5:23 PM - Patient is feeling better but wants a different medication for his headache.

5:24 PM - The patient is updated on all results and plans for discharge. He is in agreement.

Consultations:
None

Critical Care:
None

---------- **Treatment Management** ----------

Counseling: The emergency provider has spoken with the patient and discussed today's findings, in addition to providing specific details for the plan of care. Questions are answered and there is agreement with the plan. Counseling was provided regarding the diagnosis and prognosis.

ED Notes (continued)

ED Provider Notes by Gottfrid Jona Karlsson, MD at 9/1/2024 2:21 PM (continued)

---------- IMPRESSION AND DISPOSITION ----------

Medical Decision Making
29-year-old healthy male presents emergency room after MVC. Restrained driver. Rear-ended. No airbag deployment. Self extricated. Been having headache, neck pain and upper back pain since. No chest pain or abdominal pain. No weakness or numbness. No shortness of breath. Did not pass out. Physical examination here unremarkable except for mild C and T spine tenderness. No L-spine tenderness. Strength and sensation intact upper and lower extremities. No seatbelt sign noted. Extremities examined without tenderness, swelling, discoloration or reduced range of motion. Strong equal pedal and radial pulses bilaterally.
CT head and C-spine and T-spine without acute findings. Incidental findings of pulmonary nodule and thyroid nodules.
Patient given Toradol for headache here. Likely mild concussion and cervical thoracic strain. Cognitive rest recommended. Follow-up with PCP and also neurosurgery if neck and back pain persists. Tylenol and ibuprofen recommended. Good p.o. intake. Instructed seek medical attention if worsening symptoms as described in discharge instructions.

CLINICAL IMPRESSION
1. **Closed head injury, initial encounter**
2. Motor vehicle collision, initial encounter
3. Thoracic myofascial strain, initial encounter
4. Strain of neck muscle, initial encounter

DISPOSITION
DISCHARGED
5:29 PM. Reassessment at the time of disposition demonstrates that the pt is in no acute distress. He is without objective evidence for acute process requiring urgent intervention or hospitalization. The pt is stable for discharge, discussed symptomatic treatment, specific conditions for return and need for follow up with Piedmont Atlanta Hospital Emergency Department.

Prescriptions:
New Prescriptions

IBUPROFEN (MOTRIN) 600 MG TABLET	Take 1 tablet by mouth every 8 (eight) hours as needed.

The provider has reviewed the prescriptions with the patient/family and answered their questions regarding the benefits of taking the medication(s).

Patient condition:
Stable

ED Notes (continued)

ED Provider Notes by Gottfrid Jona Karlsson, MD at 9/1/2024 2:21 PM (continued)

SCRIBE ATTESTATION
By signing my name below, I, Sachi Gandhi, attest that this documentation has been prepared under the direction and in the presence of Gottfrid Jona Karlsson, *.
Electronically Signed: Sachi Gandhi, Medical Scribe. 9/1/2024 5:34 PM

PHYSICIAN ATTESTATION

I, Jona Karlsson, MD, personally performed the services described in this documentation. All medical record entries made by the scribe were at my direction and in my presence. I have reviewed the chart and agree that the record adequately reflects my evaluation/ examination of this patient.

Jona Karlsson, MD. 9/1/2024. 5:57 PM.

Note has been documented by Sachi Gandhi on 9/1/2024

Gottfrid Jona Karlsson, MD
09/01/24 1800

Electronically signed by Gottfrid Jona Karlsson, MD on 9/1/2024 6:00 PM

Final Diagnoses (ICD-10-CM)

Code	Description	POA	CC	HAC	Affects DRG
S16.1XXA [Principal]	Strain of muscle, fascia and tendon at neck level, initial encounter				
S29.012A	Strain of muscle and tendon of back wall of thorax, initial encounter				
S09.90XA	Unspecified injury of head, initial encounter				
E04.1	Nontoxic single thyroid nodule				

Discharge Information

Discharge Date/Time	Discharge Disposition	Discharge Destination	Discharge Provider	Unit
09/01/2024 1752	Home Or Self Care	None	Gottfrid Jona Karlsson, MD	Piedmont Atlanta Hospital Emergency Department

History & Physicals

No notes of this type exist for this encounter.

Consult Notes

No notes of this type exist for this encounter.

Procedure Notes

No notes of this type exist for this encounter.

Operative Notes

Operative Notes (continued)

No notes of this type exist for this encounter.

All Results

Resulted: 09/01/24 1621, Result status: Final result

CT head without contrast [1087805052]

Ordering provider: Gottfrid Jona Karlsson, MD 09/01/24 1441
Resulted by: Nikhar Kinger, MD
Performed: 09/01/24 1513 - 09/01/24 1557
Accession number: PAH33723334
Resulting lab: PHC RAD
Narrative:

CT HEAD WO CONTRAST, CT CERVICAL SPINE WO CONTRAST

INDICATION: head trauma and headache

TECHNIQUE: Helical CT images from skull base to vertex without IV contrast. Multiple-row detector helical CT examination of the cervical spine without IV contrast. Axial, sagittal, and coronal reconstructed images.

All CT scans at this facility use dose modulation and/or weight based dosing when appropriate to reduce radiation dose to as low as reasonably achievable.

COMPARISON: none
FINDINGS:
CT Head:
No acute large territory infarction. No acute hemorrhage. No significant midline shift.

No extra-axial collection.

No hydrocephalus

No acute osseous abnormality.

Paranasal sinuses are predominantly clear.

No acute orbital abnormality.

Nonspecific nasopharyngeal soft tissue fullness. High density appearance of the intracranial vessels which may be related to hemoconcentration.

CT Cervical Spine:

Alignment is maintained. Nonspecific lucent focus within the right mandible partially measured (series 4, 63). No acute, displaced fracture is identified. Vertebral body heights are maintained.

Intervertebral disc spaces are maintained.

No significant spinal canal narrowing.

Nonspecific nasopharyngeal soft tissue fullness. No prevertebral soft tissue swelling. Prominent bilateral cervical lymph nodes, nonspecific in a patient of this age. Subcentimeter bilateral thyroid nodules.

Piedmont HEALTHCARE

Alexander, Anthony Deandre Jr.
MRN: 913387030, DOB: 6/5/1995, Legal Sex: M
Adm: 9/1/2024, D/C: 9/1/2024

All Results (continued)

CT head without contrast [1087805052] (continued) Resulted: 09/01/24 1621, Result status: Final result

2 mm left-sided fissural nodule (series 5, image 220).

Impression:
1. No acute intracranial abnormality.
2. No acute fracture or traumatic malalignment of the cervical spine.
3. Bilateral thyroid nodule
4. 2 mm left-sided fissural nodule. According to the Fleischner Society Guidelines for incidentally discovered solid pulmonary nodules (MacMahon et al, Radiology, 2017): For patient's this age, no radiologic follow-up is required for nodules this size in the absence of a known history of malignancy.

Thyroid nodule recommendation: Nonemergent/outpatient thyroid ultrasound.

Electronically Signed By: Nikhar P Kinger MD 9/1/2024 4:21 PM
PARDGYRDRM005R

CT cervical spine without contrast [1087805053] Resulted: 09/01/24 1621, Result status: Final result

Ordering provider: Gottfrid Jona Karlsson, MD 09/01/24 1441 Resulted by: Nikhar Kinger, MD
Performed: 09/01/24 1513 - 09/01/24 1557 Accession number: PAH33723335
Resulting lab: PHC RAD
Narrative:
CT HEAD WO CONTRAST, CT CERVICAL SPINE WO CONTRAST

INDICATION: head trauma and headache

TECHNIQUE: Helical CT images from skull base to vertex without IV contrast. Multiple-row detector helical CT examination of the cervical spine without IV contrast. Axial, sagittal, and coronal reconstructed images.

All CT scans at this facility use dose modulation and/or weight based dosing when appropriate to reduce radiation dose to as low as reasonably achievable.

COMPARISON: none
FINDINGS:
CT Head:
No acute large territory infarction. No acute hemorrhage. No significant midline shift.

No extra-axial collection.

No hydrocephalus

No acute osseous abnormality.

Paranasal sinuses are predominantly clear.

All Results (continued)

CT cervical spine without contrast [1087805053] (continued) Resulted: 09/01/24 1621, Result status: Final result

No acute orbital abnormality.

Nonspecific nasopharyngeal soft tissue fullness. High density appearance of the intracranial vessels which may be related to hemoconcentration.

CT Cervical Spine:

Alignment is maintained. Nonspecific lucent focus within the right mandible partially measured (series 4, 63). No acute, displaced fracture is identified. Vertebral body heights are maintained.

Intervertebral disc spaces are maintained.

No significant spinal canal narrowing.

Nonspecific nasopharyngeal soft tissue fullness. No prevertebral soft tissue swelling. Prominent bilateral cervical lymph nodes, nonspecific in a patient of this age. Subcentimeter bilateral thyroid nodules.

2 mm left-sided fissural nodule (series 5, image 220).

Impression:
1. No acute intracranial abnormality.
2. No acute fracture or traumatic malalignment of the cervical spine.
3. Bilateral thyroid nodule
4. 2 mm left-sided fissural nodule. According to the Fleischner Society Guidelines for incidentally discovered solid pulmonary nodules (MacMahon et al, Radiology, 2017): For patient's this age, no radiologic follow-up is required for nodules this size in the absence of a known history of malignancy.

Thyroid nodule recommendation: Nonemergent/outpatient thyroid ultrasound.

Electronically Signed By: Nikhar P Kinger MD 9/1/2024 4:21 PM
PARDGYRDRM005R

CT thoracic spine without contrast [1087805054] Resulted: 09/01/24 1634, Result status: Final result

Ordering provider: Gottfrid Jona Karlsson, MD 09/01/24 1441
Resulted by: Nikhar Kinger, MD
Performed: 09/01/24 1513 - 09/01/24 1557
Accession number: PAH33723336
Resulting lab: PHC RAD
Narrative:
CT THORACIC SPINE WO CONTRAST

INDICATION: pain after MVC

TECHNIQUE: Multiple contiguous axial images were acquired from C7 through L1. Sagittal and coronal reformations were generated. No intravenous contrast.

All Results (continued)

Resulted: 09/01/24 1634, Result status: Final result

CT thoracic spine without contrast [1087805054] (continued)

All CT scans at this facility use dose modulation and/or weight based dosing when appropriate to reduce radiation dose to as low as reasonably achievable.

COMPARISON: None

FINDINGS:
Alignment is maintained. No acute, displaced fracture is identified. Vertebral body heights are maintained. Mild wedging of mid thoracic extending from the T5-T11 vertebral body heights which could reflect scheuermann'sdisease

There is multilevel intervertebral disc base height loss with multilevel mild areas of spinal canal narrowing.

No significant spinal canal narrowing.

There are bilateral thyroid nodules. Small amount of partially imaged anterior mediastinal soft tissue which may reflect residual thymic tissue. There is superior pericardial recess fluid. Evaluation of the lung parenchyma is degraded by motion where seen. 2 mm right lower lobe fissural nodule (series 4 image 2014).

.

Impression:
1. No acute, displaced fracture or traumatic malalignment of the thoracic spine.
2. Mild wedging of mid thoracic vertebral bodies which could reflect Scheuermann's disease.
3. Bilateral thyroid nodules.. Recommend nonemergent/outpatient thyroid ultrasound.

Pulmonary nodule recommendation: Given the patient?s age, no follow-up is required.

Electronically Signed By: Nikhar P Kinger MD 9/1/2024 4:34 PM
PARDGYRDRM005R

Testing Performed By

Lab - Abbreviation	Name	Director	Address	Valid Date Range
515 - PHCRad	PHC RAD	Unknown	2727 Paces Ferry Rd SE Atlanta GA 30339	03/18/20 1043 - Present

Patient History

Medical as of 9/1/2024

None

Medical as of 9/1/2024 (continued)

Surgical as of 9/1/2024

None

Family as of 9/1/2024

None

Family Status as of 9/1/2024

None

Tobacco Use as of 9/1/2024

Smoking Status	Smoking Start Date	Quit Date	Current Packs/Day	Average Packs/Day
Never Assessed	—	—	—	

Smokeless Status	Smokeless Type	Smokeless Quit Date
Unknown	—	—

Source
—

Alcohol Use as of 9/1/2024

None

Drug Use as of 9/1/2024

None

Sexual Activity as of 9/1/2024

None

Activities of Daily Living as of 9/1/2024

None

Social Documentation as of 9/1/2024

None

Occupational as of 9/1/2024

None

Socioeconomic as of 9/1/2024

Marital Status	Spouse Name	Number of Children	Years Education	Education Level	Preferred Language	Ethnicity	Race	Source
Single	—	—	—	—	English	Not Hispanic	Black or African American	—

Birth as of 9/1/2024

None

Piedmont HEALTHCARE

Alexander, Anthony Deandre Jr.
MRN: 913387030, DOB: 6/5/1995, Legal Sex: M
Adm: 9/1/2024, D/C: 9/1/2024

Medications

All Meds and Administrations

acetaminophen (TYLENOL) tablet 1,000 mg [1087805050]

Ordering Provider: Gottfrid Jona Karlsson, MD
Ordered On: 09/01/24 1441
Ordered Dose (Remaining/Total): 1,000 mg (0/1)
Frequency: ONCE
Status: Completed (Past End Date/Time)
Starts/Ends: 09/01/24 1445 - 09/01/24 1743
Route: Oral
Ordered Rate/Order Duration: — / —
Admin Instructions: 3250 MG/DAY MAX FOR ACETAMINOPHEN, LORTAB/VICODIN 5-325 CONTAINS 325MG,PERCOCET 5-325 CONTAINS 325MG

Timestamps	Action	Dose	Route	Other Information
09/01/24 1743	Given	1,000 mg	Oral	Performed by: Gregory A Casajuana, RN Scanned Package: 0904-6720-40, 0904-6720-40

ketorolac (TORADOL) injection 15 mg [1087805055]

Ordering Provider: Gottfrid Jona Karlsson, MD
Ordered On: 09/01/24 1728
Ordered Dose (Remaining/Total): 15 mg (1/1)
Frequency: Once
Status: Discontinued (Past End Date/Time)
Starts/Ends: 09/01/24 1730 - 09/01/24 1739
Route: Intravenous
Ordered Rate/Order Duration: — / —

Timestamps	Action	Dose / Rate / Duration	Route / Site / Linked Line	Other Information
09/01/24 1730	Due	—	—	—

ketorolac (TORADOL) injection 15 mg [1087805057]

Ordering Provider: Gottfrid Jona Karlsson, MD
Ordered On: 09/01/24 1739
Ordered Dose (Remaining/Total): 15 mg (—/—)
Frequency: Every 6 hours PRN
Status: Discontinued (Past End Date/Time)
Starts/Ends: 09/01/24 1739 - 09/01/24 1740
Route: Intramuscular
Ordered Rate/Order Duration: — / —

(No admins scheduled or recorded for this medication)

ketorolac (TORADOL) injection 15 mg [1087805058]

Ordering Provider: Gottfrid Jona Karlsson, MD
Ordered On: 09/01/24 1740
Ordered Dose (Remaining/Total): 15 mg (—/—)
Frequency: Every 6 hours PRN
Status: Discontinued (Past End Date/Time), Reason: Patient Discharge
Starts/Ends: 09/01/24 1740 - 09/01/24 2157
Route: Intramuscular
Ordered Rate/Order Duration: — / —

Timestamps	Action	Dose	Route / Site	Other Information
09/01/24 1743	Given	15 mg	Intramuscular Right Ventrogluteal	Performed by: Gregory A Casajuana, RN Scanned Package: 63323-161-21

metoclopramide HCl (REGLAN) injection 10 mg [1087805051]

Medications (continued)

All Meds and Administrations (continued)

Ordering Provider: Gottfrid Jona Karlsson, MD
Status: Discontinued (Past End Date/Time)
Ordered On: 09/01/24 1441
Starts/Ends: 09/01/24 1445 - 09/01/24 1739
Ordered Dose (Remaining/Total): 10 mg (1/1)
Route: Intravenous
Frequency: ONCE
Ordered Rate/Order Duration: — / —
Admin Instructions: 10MG OR LESS MAY BE GIVEN IV PUSH OVER 1-2 MINUTES

Timestamps	Action	Dose / Rate / Duration	Route / Site / Linked Line	Other Information
09/01/24 1445	Due	—	—	—

Encounter-Level Documents:

There are no encounter-level documents.

Order-Level Documents:

There are no order-level documents.

END OF REPORT